

2013

Mechanisms of immunity and pathology during canine leishmaniasis: Leading the way to prevention and treatment

Kevin Jan Esch
Iowa State University

Follow this and additional works at: <https://lib.dr.iastate.edu/etd>

 Part of the [Allergy and Immunology Commons](#), [Immunology and Infectious Disease Commons](#), [Medical Immunology Commons](#), [Pathology Commons](#), and the [Veterinary Medicine Commons](#)

Recommended Citation

Esch, Kevin Jan, "Mechanisms of immunity and pathology during canine leishmaniasis: Leading the way to prevention and treatment" (2013). *Graduate Theses and Dissertations*. 16084.
<https://lib.dr.iastate.edu/etd/16084>

This Dissertation is brought to you for free and open access by the Iowa State University Capstones, Theses and Dissertations at Iowa State University Digital Repository. It has been accepted for inclusion in Graduate Theses and Dissertations by an authorized administrator of Iowa State University Digital Repository. For more information, please contact digirep@iastate.edu.

Mechanisms of immunity and pathology during canine leishmaniasis:

Leading the way to prevention and treatment

by

Kevin Jan Esch

A dissertation submitted to the graduate faculty

in partial fulfillment of the requirements for the degree of

DOCTOR OF PHILOSOPHY

Major: Immunobiology

Program of Study Committee:
Christine A. Petersen, Major Professor
Justin J. Greenlee
Marit Nilsen-Hamilton
Douglas E. Jones
Annette O'Connor

Iowa State University

Ames, Iowa

2013

Copyright © Kevin Jan Esch, 2013. All rights reserved.

TABLE OF CONTENTS

LIST OF FIGURES	iv
LIST OF TABLES	vi
ABSTRACT	vii
CHAPTER 1. LEISHMANIASIS: GENERAL INTRODUCTION	1
Introduction	1
Life cycle and mechanisms of virulence	2
Clinical leishmaniasis	6
Cutaneous leishmaniasis	6
Mucocutaneous leishmaniasis	7
Visceral leishmaniasis	8
Canine leishmaniasis (CanL)	9
Pathogenesis	10
Protective immunity	12
Epidemiology and transmission dynamics	13
Cutaneous leishmaniasis	13
Zoonotic visceral leishmaniasis	16
Prevention	19
Overview of thesis and project objectives	20
References	22
CHAPTER 2. PD-1-MEDIATED T CELL EXHAUSTION DURING VISCERAL LEISHMANIASIS (VL)	37
Abstract	37
Introduction	38
Materials and Methods	40
Results	46
Discussion	59
Acknowledgements	62
References	65
CHAPTER 3. ACTIVATION OF AUTOPHAGY AND THE NOD-LIKE RECEPTOR PROTEIN 3 INFLAMMASOME DURING <i>LEISHMANIA</i> <i>INFANTUM</i> -ASSOCIATED GLOMERULONEPHRITIS (GMN)	68
Abstract	68
Introduction	69
Materials and Methods	73

Results	77
Discussion	90
Acknowledgements	96
References	96
CHAPTER 4. IMMUNOGENICITY OF A POLYPEPTIDE VACCINE FOR CANINE VISCERAL LEISHMANIASIS	101
Abstract	101
Introduction	102
Materials and Methods	106
Results	112
Discussion	122
Acknowledgements	128
References	128
CHAPTER 5. GENERAL CONCLUSIONS	134
Summary	134
Discussion	138
Immunopathology of visceral leishmaniasis	138
Immune complex-mediated glomerulonephritis	140
Future Studies	142
References	144
ACKNOWLEDGEMENTS	148
APPENDIX	153

FIGURES

CHAPTER 1

- Figure 1.1 Areas endemic for *Leishmania* species [2](#)
 Figure 1.2 The life cycle of *Leishmania* species [4](#)
 Figure 1.3 *Leishmania* parasites in culture and in a tissue section [6](#)

CHAPTER 2

- Figure 2.1 *Leishmania infantum* infection promotes progressive CD4+ T cell exhaustion [45](#)
 Figure 2.2 *Leishmania infantum* infection promotes progressive CD8+ T cell exhaustion [47](#)
 Figure 2.3 PD-1/B7.H1 interaction necessary for CD4+ T cell exhaustion during symptomatic VL [50](#)
 Figure 2.4 PD-1/B7.H1 interaction necessary for suppression of proliferation but not IFN γ production during symptomatic VL– associated CD8+ T cell exhaustion [52](#)
 Figure 2.5 *L. infantum* exhausted T cells do not undergo apoptosis or cell death in response to antigen stimulation [55](#)
 Figure 2.6 B7.H1 block increased phagocyte superoxide production and decreased parasite load. [57](#)
 Supplemental Figure 1 [63](#)
 Supplemental Figure 2 [64](#)

CHAPTER 3

- Figure 3.1 Kidney lesions associated with *L. infantum* - GMN [76](#)
 Figure 3.2 Ultrastructural lesions of VL-associated glomerulonephritis are characteristic of Type I Membranoproliferative Glomerulonephritis (MPGN) [80](#)
 Figure 3.3 VL-associated MPGN is the result of deposition of *Leishmania infantum* antigen, IgG, and C3 [84](#)
 Figure 3.4 VL-associated MPGN is associated with elevated vacuolar-associated LC-3 autophagy protein and the NLRP3 inflammasome [87](#)

CHAPTER 4

- Figure 4.1 Vaccination with Leishmania Vaccine Antigen A (LVAA) with Adenovirus vector and Canarypox vector boost induced CD4+ and CD8+ T cell proliferation after antigen stimulation [111](#)
- Figure 4.2 Vaccination with LVAA preparations induced significant CD4+ T cell intracellular and PBMC secretion of IFN γ [114](#)
- Figure 4.3 Vaccination with LVAA preparations induced significant CD8+ T cell intracellular IFN γ production [116](#)
- Figure 4.4 Vaccination with LVAA vaccine preparations resulted in limited CD4+ and CD8+ T cell production of IL-10 [120](#)
- Supplemental Figure 1 Vaccination with LVAA vaccine preparations resulted in limited PBMC nitrite production *ex vivo* [133](#)

APPENDIX

- Figure A1 Model of pan-T cell exhaustion during visceral leishmaniasis [153](#)

TABLES

CHAPTER 1

Table 1.1 Geographic locations, hosts and companion animal seroprevalence of <i>Leishmania spp.</i>	3
---	-------------------

CHAPTER 3

Table 3.1 Microscopic lesion summary of VL-associated glomerulopathy in dogs	78
--	--------------------

ABSTRACT

Visceral leishmaniasis (VL) caused by certain species of the genus *Leishmania* results in a significant disease burden worldwide. This is most pronounced in some of the world's poorest communities. In South America and the Mediterranean basin, dogs are the major domestic reservoir for *Leishmania infantum*, one cause of human VL. In addition, dogs infected with *L. infantum* have an immune response and pathophysiology similar to human cases, making them a representative naturally-occurring animal model of VL. Chronic infection with *Leishmania infantum* can result in asymptomatic infection for a long period of time, or symptomatic, potentially life-threatening visceralizing disease. Immunopathology that contributes to the precipitation of clinical disease during natural infection is incompletely understood. The goal of the research presented in this thesis was to evaluate immunopathology potentially contributing to the onset of symptomatic VL and to evaluate a potential candidate for canine vaccination against *Leishmania infantum*. Using a prospective cohort of dogs naturally infected with *L. infantum*, we identified the presence of both CD4+ and CD8+ T cell exhaustion during symptomatic VL, mediated through coinhibitory receptor Programmed Death 1 (PD-1). Blockage of the interaction of PD-1 and one of its ligands, B7 homolog 1 (B7.H1), partially recovered proliferation and IFN γ production in both CD4+ and CD8+ T cells. Furthermore, the blockage of PD-1/B7.H1 improved superoxide production in canine monocyte-derived phagocytes, and resulted in improved parasite clearance from peripheral blood after 7 days of culture. This data significantly contributes to knowledge of immunopathology during VL. In dogs with *Leishmania*-associated glomerulopathy, we evaluated glomerular lesions, describing the occurrence of a type I membranoproliferative glomerulonephritis, with expansion of the mesangium and podocyte retraction with

mesangial cell interposition. These lesions were associated with glomerular deposits containing *L. infantum* antigen, IgG, and to a lesser extent, complement protein C3b. Symptomatic disease was associated with increased glomerular Nod-like receptor protein 3 (NLRP3) and increased positivity for the autophagy marker Microtubule-associated protein light chain 3 (LC3). This research expands the characterization of *Leishmania*-associated glomerulonephropathy, and the presence of inflammasome activation and autophagy during immune complex glomerulonephritis. The final chapter of this thesis evaluates a vaccine candidate for prevention of canine leishmaniasis. This research demonstrates the immunogenicity of this vaccine candidate after administration. As a whole, the work presented herein is a significant advancement of the understanding of the pathophysiology and immunopathology of canine infection with *Leishmania infantum* with potential correlates to human VL, and a report of the immunogenicity of a potential canine leishmaniasis vaccine.

CHAPTER 1

LEISHMANIASIS: GENERAL INTRODUCTION

Kevin J. Esch and Christine A. Petersen

Excerpt from a manuscript published in *Clinical Microbiology Reviews* [1]¹, and a excerpts from book chapter to be submitted as a book chapter in *Pathobiology of Human Disease: A Dynamic Encyclopedia of Disease Mechanisms*²

INTRODUCTION¹

There are over 77 million dogs and 93 million cats in our households in the United States alone. Approximately 62% of households have at least one pet and over half of these have multiple pets (APPA) [2]. Various studies have demonstrated the importance of pets in overall health, well-being, and for providing social support [3-6]. Consistent with this devotion to pets, owners in the US spend approximately \$10.94 billion annually on pet supplies and over-the-counter pet medications and \$14.11 billion on veterinary care annually [2]. Given the number of companion animals in the United States and the bond with their owners, awareness and prevention of the zoonotic diseases of our companions is of paramount importance. Protozoal diseases, such Chagas' disease and leishmaniasis, are insidious with high numbers of asymptomatic animals able to transmit disease. *Giardia duodenalis* and *Toxoplasma gondii*, endemic to the United States, have a high prevalence in companion animals [7, 8] (Figure 1.1). *Leishmania* species and *Trypanosoma cruzi* are regional and have a low prevalence within the United States, but are significant sources of human disease world-wide and are re-emerging and expanding their geographic distribution in companion animals in the United States [9, 10]. Thankfully, we are generally protected by intact immune systems and our health is bolstered by good nutrition, sanitation and hygiene,

but immunocompromised individuals, including the growing number of obese and/or diabetic individuals in the United States are at much higher risk for developing any zoonosis [11, 12].

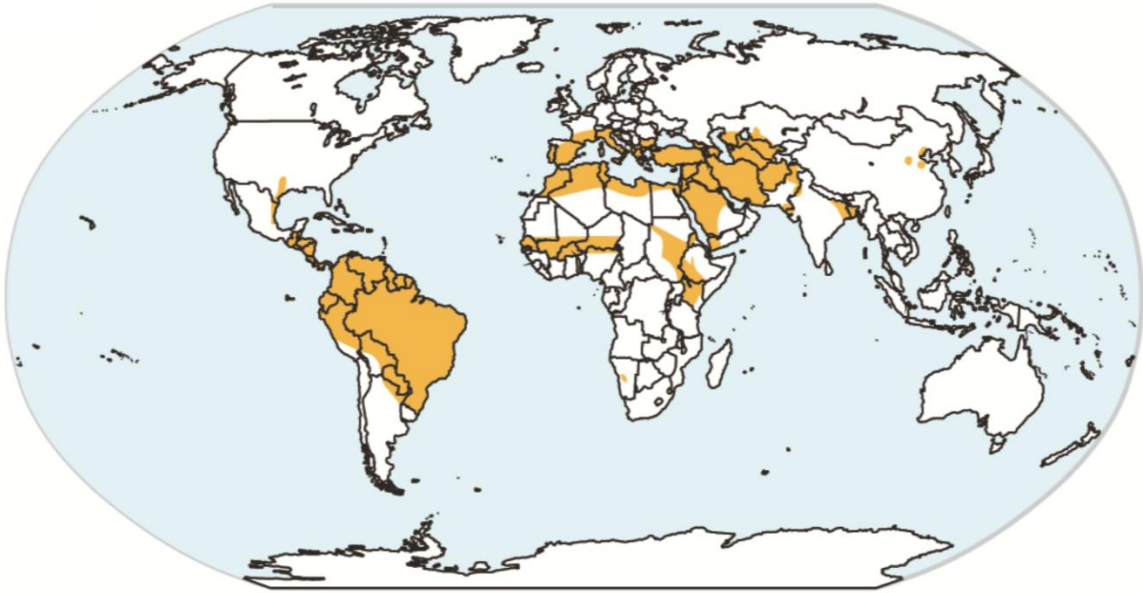


Figure 1.1. Areas endemic for Leishmania species

As such, awareness of these often neglected diseases in veterinary and human health communities is important for protecting pet health and preventing human disease. In this article, we will review mechanisms of virulence, epidemiology, transmission, and clinical signs of zoonotic protozoal pathogens of consequence to pet owners in the United States.

LIFE CYCLE AND MECHANISMS OF VIRULENCE¹

Leishmaniasis is a vector borne disease caused by species of *Leishmania* from the family *Kinetoplastidae*. Infection with *Leishmania spp.* can result in a spectrum of clinical disease dependent upon the infecting species. Visceral Leishmaniasis (VL) is caused by *L.infantum* in the Americas and Mediterranean basin, and *L. donovani* in India, sub-Saharan

Table 1.1. Geographic locations, hosts and companion animal seroprevalence of *Leishmania* spp.

Disease entity	Species	Area(s) of endemicity	Predominant reservoir(s)	Canine seroprevalence	Reference(s)
Cutaneous Leishmaniasis	<i>Leishmania major</i>	Middle East, northwestern China, Northwestern India, Pakistan, Africa	Gerbil species, Jird, Fat Sand Rat	Egypt, 3 cases, Saudi Arabia. 3 cases	[13-20]
	<i>L. aethiopica</i>	Ethiopia, Kenya, Somalia	Rock Hyrax		[21, 22]
	<i>L. mexicana</i>	Central America, Mexico, TX	Yucatan Deer Mouse, Tree rat, other rodents	Mexico, 30.2%, 10.5% ^a , TX, 8 cases ^a	[23-28]
	<i>L. amazonensis</i>	Brazil	Various forest rodents (grass, pygmy mice)	Brazil, 1 case	[29, 30]
	<i>L. tropica</i>	Mediterranean, Middle East, Western Asia, Indian subcontinent	Human, foxes, golden jackals, hyrax, dogs	Morocco, 8 cases	[31-35]
	<i>L. braziliensis</i>	Central, South America	Forest mammals, marsupial species, opossum	Mexico, 8.2%, 11.57% ^a , Brazil, 2-3%	[27, 28, 36-39]
	<i>L. guyanensis</i>	Guyana, Suriname, northern Amazon basin	Two-toed sloth, Forest mammals, marsupial species, opossum	Colombia, 2.2%	[40, 41]
	<i>L. peruviana</i>	Peru, Argentinean highlands	Dog?	Peru, 1.8% ^b	[42]
	<i>L. shawi</i>	Brazil	Cebus monkeys, sloths, pro-cyonids		[43]
	<i>L. lainsoni</i>	Brazil, Bolivia, Peru	Lowland Paca, Rodents		[44]
<i>L. naiffi</i>	Brazil, French Guyana, Ecuador, Perú	Armadillos		[45]	
<i>L. venezuelensis</i>	Venezuela	Unknown, cat?	Venezuela, 6 cases ^a	[46]	
<i>L. panamensis</i>	Panama, Costa Rica, Colombia	Sloths, kinkajous, marsupial species, opossum	Colombia, 12 cases, Panamá, 3.3%, Ecuador, 2 cases	[47-51]	
Visceral Leishmaniasis	<i>L. donovani</i>	Indian subcontinent, northern and eastern China, Pakistan, Nepal, Eastern Africa, Sudan, Kenya	Human, dogs , goats	Sudan, 2 cases, Ethiopia, 14.8%, India, 6.5%	[52-55]
	<i>L. infantum</i> (syn. <i>chagasi</i>)	Middle East, Mediterranean basin, northern and northwestern China, northern and sub-Saharan Africa, Central and South America	Dogs , foxes, jackals, wolves	Mexico, 11.9%, 22.10% ^a , Brazil, 7.14%-57%, Portugal, 4.3-25.2%, Spain, 8.1-13%, Italy, 2.6%, France, 4-8%, Greece, 2-30%, Uzbekistan, 32.1%, Turkey, 20.7%, China, 23.5-28.2%, Iran, 14.2%, 10%ab, Jerusalem – 6.7% ^a , Senegal, >40%	[27, 28, 35, 37, 56-83]

^a - Feline seroprevalence.

^b - Prevalence was measured from positivity on skin or splenic biopsy and culture.

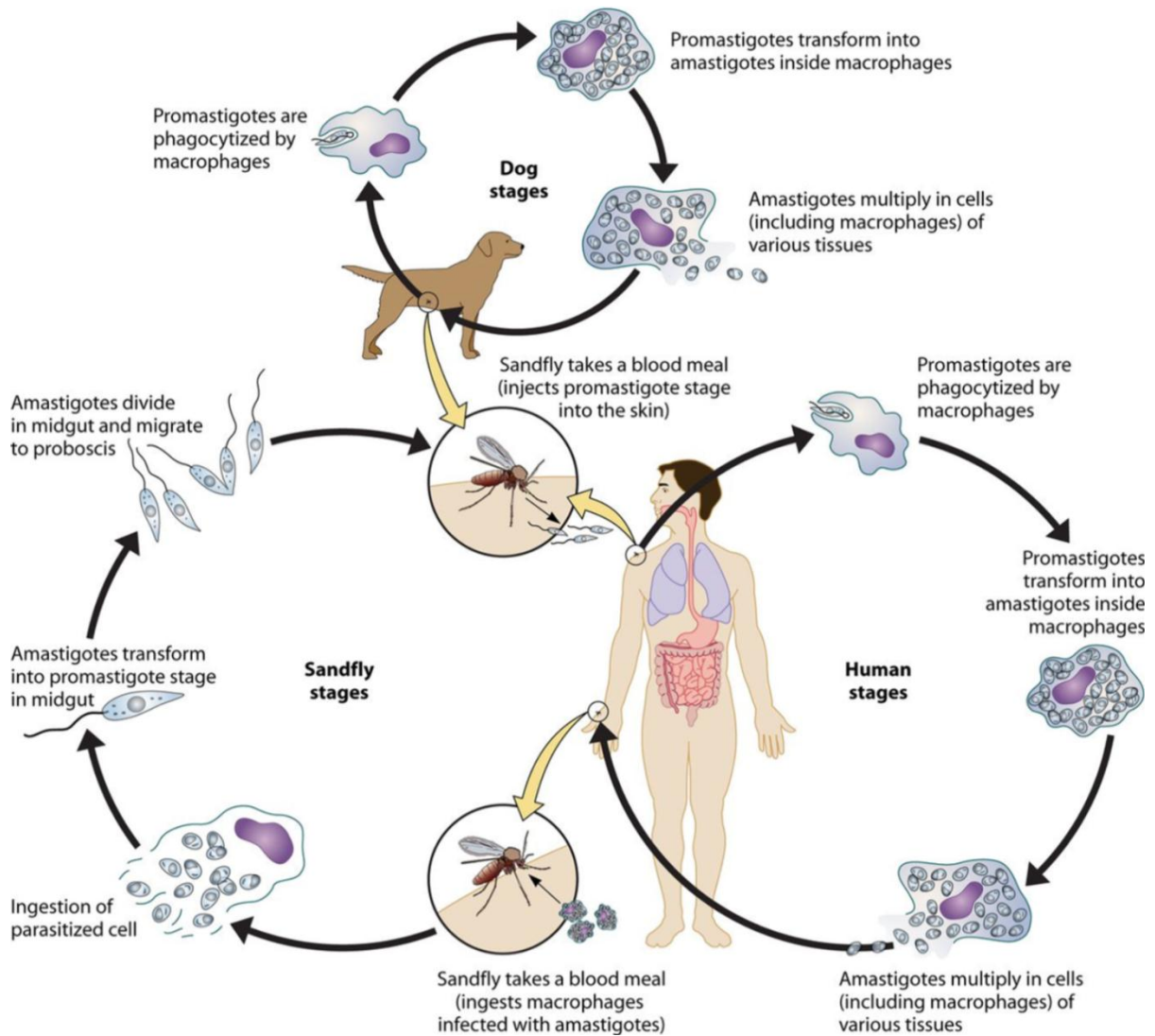


Figure 1.2. The life cycle of *Leishmania* species. Sandflies inject infective promastigotes into a susceptible mammal during feeding. Promastigotes are phagocytised by resident phagocytes, transform into tissue-stage amastigotes, and multiply within these cells through simple division. The parasite continues to infect phagocytic cells either at the site of cutaneous infection or in secondary lymphoid organs, with eventual parasitemia. Sandflies become infected through feeding on a host either with an active skin lesion in CL or with parasitemia in VL. Parasites convert to promastigotes within the sandfly midgut. Promastigotes migrate from the midgut and transform into highly infectious metacyclic promastigotes.

Africa, and Asia. Occasionally cases of VL will arise from cutaneous disease-causing species, and occurred in United States troops due to infection with *L. tropica* [84]. VL arises from parasitic infection of phagocytic cells within secondary lymphatic organs (spleen, lymph nodes), liver, and bone marrow. Cutaneous forms of Leishmaniasis (CL) (Table 1.1) arise from infection of epidermal tissue after promastigote inoculation into the host. In susceptible hosts and immunocompromised persons, disseminated cutaneous or diffuse cutaneous leishmaniasis may occur as a rare but severe manifestation CL. A third form of the disease, Mucocutaneous Leishmaniasis (MCL), arises from a small percentage of cutaneous cases that cleared disease months or years prior to the onset of MCL. MCL often begins with involvement of the nasal mucosa, including generalized inflammation and ulceration. Ulceration and necrosis of these areas may be severe, resulting in disfigurement and occasionally death. Mechanisms of mucocutaneous lesion formation are poorly understood, but a *Leishmania* RNA virus (LRV1), was associated with severe mucocutaneous lesions through a TLR3-dependent inflammatory response [85].

Life cycles of *Leishmania species* are relatively simple involving mammalian hosts and vector stages (Figure 1.2). Vectors for the various species of *Leishmania* are phlebotomine sandflies of the genus *Lutzomyia* in the Americas and *Phlebotomus* in other endemic regions. The sandfly injects infective promastigotes into a susceptible mammal through its proboscis during feeding. Promastigotes (Figure 1.3A) are quickly phagocytized by resident phagocytes, transform into tissue stage amastigotes, and survive and reproduce within these cells through simple division in a parasitophorous vacuole. Depending upon host and parasite factors the parasite continues to infect phagocytic cells either at the site of cutaneous infection or in secondary lymphoid organs with eventual parasitemia (Figure 3B).

Sandflies subsequently become infected through feeding on a host either with an active skin lesion in CL or with parasitemia in VL. Parasites convert back to metacyclic promastigotes

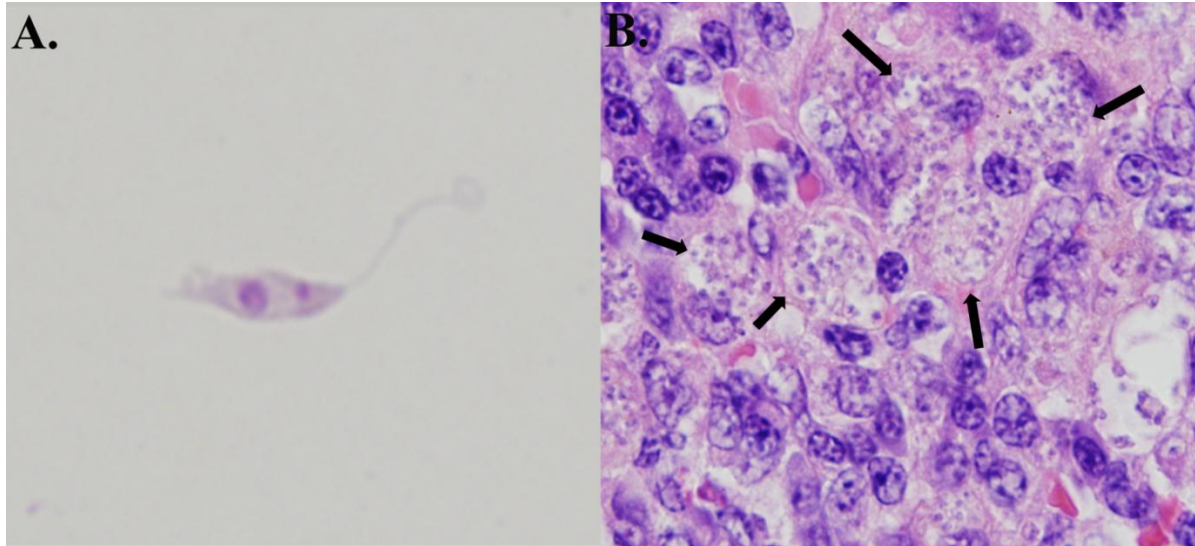


Figure 1.3. *Leishmania* parasites in culture and in a tissue section. (A) *Leishmania amazonensis* promastigote from culture with a visible kinetoplast. (Photo by Pedro Martinez.) (B) Zoonotic visceral leishmaniasis in canine spleen. The spleen was enlarged and infiltrated by large numbers of foamy macrophages containing numerous intracellular *Leishmania infantum* amastigotes (arrows), confirmed by immunohistochemistry (magnification, $\times 100$).

within the sandfly midgut and reproduce to high numbers within 4-14 days. These promastigotes migrate from the midgut to the salivary glands where they await the initiation of feeding.

CLINICAL LEISHMANIASIS²

Cutaneous leishmaniasis

The disease categorization of leishmaniasis encompasses a spectrum of disease forms (cutaneous, mucocutaneous, visceral) and symptoms of varying severity [86, 87]. Cutaneous

lesions develop weeks to months after the sandfly bite, and are usually present on regions of the skin exposed to the sand fly bite [88]. Lesions are focal, and can be single, multiple or less commonly disseminated [89-91]. In non-endemic regions where CL is a less likely differential, repeated attempts at antibiotic or steroid therapy are unsuccessful. Lesions range grossly from small erythematous papules to nodules, scaly plaques, or ulcerated exudative lesions [89-91]. Regional lymphadenopathy is common in reaction to the migration of infected dendritic cells (DC) and macrophages to secondary lymphoid organs. Lesions are commonly self-limiting, with resultant depigmented scar [92]. Disseminated Cutaneous Leishmaniasis (DCL) is a rare presentation of CL, even in hyper-endemic regions, and is thought to be the result of host immunopathology in the form of a grossly inadequate Th1 response [93-96]. Initial infection progresses much like uncomplicated CL, with subsequent progression to diffuse, non-ulcerated, macules, papules, and plaques. Due to the aberrant immune response during DCL, these lesions have extremely high numbers of amastigotes compared to typical CL lesions [95]. Generalized lymphadenopathy is common due to lymphatic spread of the *Leishmania spp.* amastigotes [95, 97].

Mucocutaneous leishmaniasis

Mucocutaneous leishmaniasis (ML), is typically more severe than CL and is not self-limiting. ML is a known risk from *Leishmania* species of the *Viannia (V)* subgenus, typically found in Central and South America (*L. (V.) braziliensis*, *Leishmania (V.) amazonensis*, *L. (V.) panamensis*, and *Leishmania (V.) guyanensis*) [98, 99]. The pathogenesis of ML is not fully elucidated, but is associated with host immunopathology, similar to DCL, and parasite virulence. Recent research indicates a *Leishmania* RNA virus (LRV1) was associated with

severe mucocutaneous lesions through a TLR3-dependent inflammatory response [85]. MCL often begins with involvement of the nasal mucosa, including generalized inflammation and ulceration [86, 100]. Ulceration and necrosis of these areas may be severe, resulting in disfigurement and occasionally death. Lesions arise on the nasal or oral mucocutaneous junctions, which may progress to other regions of the skin or oropharynx [100]. Nasal septal granulomas can be found with endoscopy or nasal biopsy [86, 100]. These lesions will progress to palatal ulcerations, with or without erythema and edema of the nares, nasal septum perforation, palatal ulceration, gingival edema, and periodontitis [101, 102]. Eventually, there is progressive destruction of the oronasopharyngeal mucosa, and cartilaginous facial and upper airway structures, resulting in disfiguration, secondary infection, and airway obstruction [92, 101, 102].

Visceral leishmaniasis

Visceral leishmaniasis (VL), caused by multiple species of *Leishmania*, is invariably fatal if left untreated [87]. The incubation period is variably and can range from a few weeks to years after exposure, depending upon the intensity of exposure and the immune competence of the patient. Onset is usually gradual with progressive weight loss, intermittent fever, pain, and weakness, although rapid onset VL with high fever can occur [103]. In symptomatic patients the spleen is large, firm, and palpable (splenomegaly), with or without hepatomegaly [103]. Lymphadenopathy is common with dissemination of amastigote-containing macrophages throughout the secondary lymphoreticular system. Hematologic abnormalities arise due to splenic and bone marrow infection, and result in ecchymoses, petechiae, extra-vascular hemolysis, and peripheral edema [103]. Clinical chemistry

abnormalities include anemia, thrombocytopenia, neutropenia, and pronounced hypergammaglobulinemia [103]. Circulating immune complexes are commonly associated with high levels of infection and hypergammaglobulinemia and can result in the formation of rheumatoid factors and glomerulonephritis in approximately 25-30% of human cases [104]. Co-morbidity with HIV infection can result in atypical presentation due to leukocyte depletion, in which disseminated infection to numerous tissues occurs in approximately 1/3 of HIV/VL cases [101].

Canine leishmaniasis (CanL)

Canine infection, primarily with *Leishmania infantum*, results in visceralizing disease with a similar, but not entirely overlapping presentation compared to human VL. The clinical presentation varies and includes dermal lesions, splenomegaly, generalized lymphadenopathy, cachexia, anorexia, muscle wasting, polyuria and polydipsia, keratoconjunctivitis, nail overgrowth, and hematologic abnormalities [105-107]. Splenic and hepatic lesions are similar to human VL with granulomatous splenitis characterized by large numbers of amastigote-infected macrophages, and lymphoplasmacytic and granulomatous portal and periportal hepatitis. Skin lesions are one of the most common presenting signs in endemic regions and can include non-pruritic dermatitis, ulcerative dermatitis, focal or multifocal nodular dermatitis, proliferative dermatitis, or mucocutaneous ulcerative or proliferative dermatitis [106, 108]. With these lesions, secondary bacterial pyoderma is the most common complicating co-morbidity. Histologically, these lesions are granulomatous or pyogranulomatous with acanthosis, orthokeratotic and hyperkeratotic hyperkeratosis, and ulceration with serocellular crust formation. Lymphoplasmacytic vasculitis and peri-

vasculitis may also be present. Renal disease is present to some degree, in nearly 100% of infected dogs, compared to 25-30% in humans [109, 110]. Lymphoplasmacytic and granulomatous interstitial nephritis is invariably present. Glomerular alterations vary by symptomatic state of the animal and the degree of hypergammaglobulinemia, and can range from minimal change glomerulonephritis to mesangioproliferative and/or membranoproliferative glomerulonephritis, to glomerulosclerosis present in combination with the nephrotic syndrome [109, 110]. Ocular lesions may also occur in approximately 16% of patients, depending on disease severity. Common manifestations are conjunctivitis, blepharitis, and anterior uveitis [107]. CanL is a disease similar in presentation and clinical signs to human infection, and naturally infected dogs are a representative pathologic and immunologic model of human VL.

PATHOGENESIS²

Leishmania species have a unique pathogenesis and means of persistence within host cells enabling the establishment of long term chronic infection. After a sand fly bite, an influx of both neutrophils and macrophages occurs, even in the absence of parasites [111]. At this stage the metacyclic *Leishmania* promastigotes are relatively immobile compared to other kinetoplast species [111]. Sand fly-derived salivary chemoattractants promote an influx of both neutrophils and macrophages at feeding site [111]. Infection of neutrophils, macrophages, and dendritic cells occurs at this stage of infection [111, 112]. Parasites inhibit phagosome acidification allowing survival within neutrophils, but have not been shown to transform into amastigotes or proliferate within neutrophils [113]. At the time of neutrophil apoptosis, surviving parasites are phagocytosed by resident and infiltrating macrophages,

where the parasites will transform into amastigotes, replicate, and establish long term infection. The utilization of neutrophil apoptosis as a means of macrophage entry may be a unique evolutionary adaptation of the parasite for survival [111]. Dermal dendritic cells also become infected at the site of inoculation, becoming mature and migrating to regional lymph nodes. This can be inhibited by pathogenic species *L. amazonensis* through enhanced ERK signaling from the phagosome resulting in improper dendritic cell maturation and decreased production of IL-12, a key pro-inflammatory mediator [114]. *Leishmania* phagocytosis is mediated through complement receptors 1 (C1), 3 (C3), and mannose scavenger receptors, indicating both opsonization-dependent and independent mechanisms of invasion [115]. Uptake results in reorganization of F-actin and delayed phagolysosomal fusion [115, 116]. *Leishmania* are resistant to acidification as amastigotes, and persist in these compartments that are late endosome associated LAMP1, Rab7 positive vacuoles [117]. Amastigotes persist and replicate within the phagolysosome until eventual host cell lysis occurs. The ability of the parasite to direct phagosome trafficking and delay phagolysosome fusion is dependent upon surface lipophosphoglycans with differing side chains [117-119]. *Leishmania* species are also able to acquire nutrients needed for survival through the expression of LIT-1 to acquire Fe^{2+} needed for growth and survival [120].

Leishmania utilize a number of immune evasion strategies to inhibit the immune response including the interruption of DC maturation as mentioned earlier, the stimulation of anti-inflammatory cytokines such as TGF- β and IL-10, the interruption of cellular signaling of the STAT pathways necessary for IFN γ production, and through the induction of CD25+, FoxP3+ T regulatory cells.

PROTECTIVE IMMUNITY²

The immune response to all *Leishmania* species as an intracellular pathogen is dependent upon a timely and appropriate Th1 response including IL-12 production by dendritic cells and macrophages, efficient MHC II presentation, and subsequent IFN γ production from T cell populations. In addition, cytokine secretion at the site of inoculation by keratinocytes may play an integral role in Th1 differentiation and parasite clearance including secretion of IL1 β , IL-6, IL-12, and IL-4 [121]. Innate immune system clearance of *Leishmania* is dependent primarily upon intra-cellular killing via superoxide and nitric oxide within phagolysosomes of infected macrophages, which is enhanced with IFN γ stimulation from NK cells early in infection and T cells at later stages. Neutrophils recruited to the inoculation site from the presence of sandfly saliva may be permissive to *Leishmania* growth, and the presence of neutrophils and of high levels of IL-17 have been associated with increased parasite load in CL, even amidst a robust cell mediated immune response [111, 122]. While the correlates of protective immunity against *Leishmania spp.* are thought to be understood (high IFN γ , low IL-10 and low IL-4), the development of protective immunity through vaccination has proven challenging. For CL, leishmanization, skin inoculation with lesion exudate from infected patients in an inconspicuous area, is effective, providing long-term immunity [123, 124]. However, this method can result in clinical disease as there are persistent parasites at the inoculation site [125, 126]. Whole-killed parasites have also been used, but their efficacy has been poor [127]. Second generation vaccines utilizing multiple immunogenic peptides in a fusion protein or genetically-modified, non-replicating *Leishmania* vaccines have demonstrated potential as vaccine platforms [128-133]. One of the only currently approved canine vaccines in Brazil, contains a fucose-mannose ligand of *L.*

donovani with saponin adjuvant, with an approximate reduction in clinical disease by 60-75% after 2 years [134, 135]. This vaccine does result in a high rate of adverse localized vaccine reactions. There are no currently approved human vaccines against any *Leishmania* species.

EPIDEMIOLOGY AND TRANSMISSION DYNAMICS¹

Leishmania is endemic in 98 countries and 3 territories, with a high percentage of cases occurring in developing nations [136]. The distribution of competent vector species and leishmaniasis has expanded over the last decade, possibly due to an increasingly amenable environment of vector species, due to shifts in climate [137]. This results in approximately 200-400,000 cases of VL and 700,000 to 1.2 million cases of CL each year resulting in an estimated 20,000 to 40,000 deaths [136]. Greater than 90% of global VL cases occur in India, Bangladesh, Sudan, South Sudan, Ethiopia, and Brazil [136]. Among the 15 disease-causing species of *Leishmania*, 13 are thought to have some degree of zoonotic transmission, and in the case of *L. infantum*, dogs are the main reservoir, largely responsible for the transition from sylvatic to domestic transmission cycles [10, 56]. The multiple clinical forms of leishmaniasis will be discussed briefly in this review, primarily based on the degree of zoonotic transmission from companion animal species.

Cutaneous leishmaniasis

CL is caused by one of a number of *Leishmania* species with widespread distribution and includes a variety of location-specific reservoir species (Table 1). In the old world *Leishmania major* is a widespread cause of CL. The reservoirs for *L. major* vary by location

but include a number of species of rodents. Population densities of these reservoirs and vectors are significantly tied to the seasonality of infection and increases in reservoir rodent population have been associated with numerous zoonotic cutaneous leishmaniasis (ZCL) outbreaks [56, 138]. *L. aethiopica* also causes ZCL and appears to be isolated to the highlands of Ethiopia. Reports have identified this species at lower altitudes as well, indicating that perhaps the distribution is more widespread, or that the area of endemicity is expanding [21]. CL caused by *L. tropica* is considered anthroponotic. However animal species can be infected and have been suggested as potential reservoirs, including the domestic dog (Table 1).

In the New World, numerous species of CL-causing *Leishmania* species are present, all of which have been identified in multiple mammalian species. *L. mexicana* is found from Central America to the Yucatan peninsula in Mexico, and cases have been reported in Texas [23, 139-141]. There have been a number of isolated reports of companion animal cases that have not been travel associated in Texas [23, 139-141]. Notably, many of these cases of zoonotic CL were in cats [23, 139, 141], perhaps due to their more outdoor lifestyle. There have been 30 autochthonous cases of human CL in Texas through 2008, where CL is considered endemic [24]. While companion animal infection and transmission may occur, the predominant reservoir in Texas is considered to be the Southern Plains woodrat, *Neotoma micropus* [25]. There are vectors capable of dissemination of this species throughout the southern United States and it is likely that disease due to *L. mexicana* will increase in the United States over time [137].

South American species of *Leishmania* causing CL, including *L. amazonensis*, *L. brasiliensis*, *L. guyanensis*, *L. panamensis* have sylvatic reservoirs. Two species causing CL

in South America are thought to have domestic animal reservoirs. *L. venezuelensis* has been identified in several urban and peri-urban areas of Venezuela and it is suspected that the domestic reservoir species are infected cats [46]. *L. peruvianensis*, a species once limited to altitudes of 1200-3000 meters in the Peruvian Andes, uses the dog as a primary reservoir although limited evidence of canine transmission to sand flies exists [42]. In all, there exists a potential for zoonotic transmission of cutaneous leishmaniasis from companion animals, most notably the dog. While there are numerous reports of canine and feline infection and clinical disease with ZCL, their role as a reservoir has not been definitively established.

Human risk factors for ZCL primarily are dependent upon exposure to the various vector species, and the presence of populations of appropriate reservoir species. In all cases, urbanization and encroachment on wilderness areas has resulted in increased interaction between human, reservoir and vector species, and establishment of urban domestic life cycles rather than sylvatic cycles. The establishment of urban domestic transmission cycles holds the potential for larger outbreaks of ZCL due to the spread between naïve human hosts during everyday life versus occasional infection due to human introduction into the sylvatic cycle. Deforestation and agricultural development including damming of water and irrigation also create new environments with food sources optimal for the survival of reservoir rodent species. An outbreak in Mazar-e Sharif in northern Afghanistan was traced to exploding population of *Rattus opimus* in an area of irrigation canal construction [138]. *L. guyanensis* in Brazil developed urbanized lifecycles within Brazil and increased risk of infection dependent upon household distance from the forest [142, 143]. Interestingly, long-term surveillance in Bahia, Brazil suggests that the number of cases in agricultural workers has

decreased in the last 20 years, with an overall increase in disseminated disease, and in coastal areas [144].

Recent studies have identified being younger in age (5-19), sleeping without bed nets, ownership of dogs and cattle, and the presence of organic animal material as associated with a higher risk of infection.[145]. Additionally social factors such as low education and income increase the likelihood of exposure due to poor housing and environments conducive to vector presence. These include having mud-walled housing (not brick or concrete), having dirt streets and/or floors, and cleanliness of the domestic environment, and working in forested areas [146-148].

Zoonotic Visceral Leishmaniasis (ZVL)¹

Visceral leishmaniasis is caused by *Leishmania donovani* in India, areas of Asia, Sudan, South Sudan, Kenya, and Ethiopia, and by *Leishmania infantum* (syn. *L. chagasi*) throughout South America, in areas of Central America and Mexico, the Mediterranean basin, Middle East, central and southwestern Asia, northwestern China, and northern and sub-Saharan Africa. Transmission of *L. donovani* is considered solely anthroponotic, although animal infections have been reported, and reservoir status has been suggested for dogs in Sudan and for goats and possibly other species in Nepal [52, 53].

Zoonotic infection with *L. infantum* is responsible for the majority of zoonoses-based human cases of VL. As with other species of this genus, the vectors for *Leishmania* in the New World are *Lutzomyia* species, predominantly *Lutzomyia longipalpis*, and in the Old World are a number of species from the genus *Phlebotomus*. Canids are considered both the primary sylvatic and domestic reservoir, with foxes, jackals, and wolves filling the role of

sylvatic reservoirs and the domestic dog serving as the domestic reservoir [10, 56]. There is also data suggesting that wild felids can be susceptible to infection, although their definitive role in transmission is unclear [149]. Similarly, domestic cats in endemic areas of Brazil can be infected and could pose as potential secondary reservoirs [57]. Humans are relatively resistant to *L. infantum* and have a high rate of asymptomatic infection. The WHO estimated 200,000-400,000 clinical VL cases to be a gross underestimate of the burden of human *L. infantum* infection worldwide [150]. If a patient has immunologic control of *L. infantum* infection, low or absent parasitemia and compartmentalization of the parasite within the secondary lymphoid organs and bone marrow may reduce the likelihood of transmission to sand flies. When ZVL occurs in immunocompromised persons or animals, parasite load increases and transmission, as well as clinical disease, is likely to occur.

The role of the domestic dog in maintenance and transmission of *L. infantum* is clear. In Brazil, infected dogs in urban and peri-urban endemic areas are common, accompanied by a sufficient environment for *L. longipalpis* [58]. Vertical transmission has been documented in the dog, suggesting a vector-independent means of transmission [151]. In northeastern Brazil, there was a reported seroprevalence rate of 32.5%, with parasitemia in almost 47% of seropositive dogs [58]. In southeastern Brazil, seroprevalence rates in dogs ranged between 15.9% in urban areas and up to 57% in endemic rural areas [59, 60]. In endemic Mediterranean areas canine seropositivity ranged from approximately 8.1% in central Spain, 13% in southern Spain, and between 4 and 25% in Portugal, France, Italy, Greece, Cyprus, and Turkey [62, 152, 153]. The presence of these animals was significantly correlated to human risk, but incidence of human disease varied by country and region [154]. In Europe the estimated incidence rate of human ZVL ranges from 0.02-0.47 per 100,000 except in

Turkey where a higher 1.6-8.53 cases/100,000 people was reported [58, 59, 61, 155, 156]. In endemic areas of Brazil the incidence of VL was much higher with twice the number of cases of the entire Mediterranean region from 2004—2008 [58, 59].

Risk factors for ZVL in large part relate directly to the differences in incidence of human disease in Brazil and Europe. Numerous studies have demonstrated risk for ZVL based on the presence of dogs within the household, the housing type (comparing mud-walled housing to concrete or brick housing), education level, income, and disease knowledge [157]. Clinical ZVL has also been associated with poorer nutrition [157]. Many of the same factors associated for human ZVL also apply to owner characteristics associated with risk for canine VL [158]. Vertical transmission has been characterized in the dog and suggested in humans causing an increased risk of infants born to parasitemic mothers [159]. Treatment of pregnant women with liposomal amphotericin B appears to be successful in reducing the occurrence of congenital VL [160]. Additional risk factors for humans are related to their immunologic status and ability to clear infection or maintain an asymptomatic state. These include concurrent infection with HIV, co-infections with helminth parasites, drug abuse, and suppression of the immune system for any reason. These co-morbidities, especially HIV co-infection, confer a higher risk of the development of ZVL [158]. The risks for dogs also include co-infection with other parasites, rickettsial diseases, heartworm disease, or immune suppression [160, 161]. Genetic susceptibility may also be a factor for the development of clinical disease. Large scale studies conducted in numerous countries have indicated a role for genetic susceptibility including polymorphisms of a number of metabolic genes, iron metabolism genes, chemokines and cytokines, and HLA alleles [162].

This suggests a complex evolutionary interplay of parasite and host factors, which are likely associated with disease susceptibility.

PREVENTION

Prevention of Leishmaniasis requires blocking a step in the parasite's life cycle. Interrupting sandfly transmission is of primary importance for individual and community protection from CL and VL. Avoiding being outside during times of sandfly feeding, typically from dusk until dawn, can greatly reduce transmission. Wearing topical insect repellents and utilizing permethrin treated bed nets or clothes are also effective in repelling sand flies [163-165]. In domestic areas residual household sprays have been utilized to reduce the presence of the vector, but inconsistent compliance with periodic spraying, cost, and concerns over insecticide resistance limit the efficacy of this type of intervention on a widespread, long-term basis.

Approaches to address reservoir populations have also been implemented in an attempt to reduce ZVL. Brazil has implemented public health policy utilizing voluntary surveillance and culling of positive dogs to reduce the burden of VL [158]. While studies have shown that vigilant surveillance and culling can reduce the canine prevalence of VL to a degree, impacts on human infection are more difficult to ascertain [159]. Limitations in diagnostic sensitivity likely leads to false-negative diagnosis in a large number of asymptomatic dogs, delays between testing and dog removal increase the likelihood of transmission, and the financial and emotional cost of the implemented policy in Brazil is high [61, 159, 166]. The use of permethrin or deltamethrin collars or topical applications have shown efficacy in reducing sandfly feeding and transmission in endemic areas [167, 168].

However, the cost and necessity for reapplication make these interventions more difficult to utilize in many endemic regions. Limiting the degree of human infection is also important for control and prevention of severe clinical disease. Public health efforts have resulted in a reduction of severe cases in Brazil. There is currently no vaccine for human leishmaniasis. Continued research may result in a vaccine with long-term, efficacious, protection.

THESIS OVERVIEW AND PROJECT OBJECTIVES

Leishmaniasis afflicts between 1.5 and 2 million people across the world annually, and is endemic in 98 countries and 3 territories [136, 137]. The number of asymptomatic infections with *Leishmania infantum*, a causative agent of visceral leishmaniasis, is high compared to symptomatic disease. In one Brazilian study, exposure measured by the Montenegro skin test (a delayed type hypersensitivity skin test) was 71.3% compared to 9.7% positive via ELISA [169]. Seroconversion is often associated with progression toward symptomatic VL. This indicates a high number of asymptomatic infections compared to individuals progressing toward clinical disease. The mechanisms that lead to the precipitation of symptomatic VL are poorly understood. Furthermore, symptomatic *Leishmania* infections are associated with immune pathology, including alterations in T cell function, in macrophage phenotype and function, and in B cell responses [170, 171]. The B cell response during chronic VL becomes pathologic, driving a hypergammaglobulinemia and subsequent immune complex deposition in tissues such as the renal glomerulus [106]. This occurs in nearly 100% of dogs with VL and in approximately 25-30% of human VL patients [104, 106]. Developing effective means of prevention or immunotherapy during *Leishmania* infection has proven difficult. Vaccination platforms for VL in humans and dogs have thus

far been ineffective or have a high rate of adverse events, paired with efficacy measured as a prevention of clinical disease, and not necessarily of transmission capability [127]. Natural canine infection with *Leishmania infantum* is pathologically and immunologically similar to human VL caused by the same pathogen, and is also of direct public health importance as the main domestic reservoir for human infection.

The objectives of this thesis were characterize natural *Leishmania infantum* infection in the dog as 1) an immunologic and pathologic model of human VL, 2) as a model of immune complex-mediated glomerular disease, and 3) to directly address prevention of CanL. The results generated by the research in this thesis contribute significantly to the understanding of mechanisms leading to the onset of clinical VL, through a novel description of T cell exhaustion during symptomatic VL, mediated through a gradual increase in coinhibitory surface receptor Programmed Death 1 (PD-1). This T cell exhaustion results in impaired macrophage production of reactive oxygen species (ROS), and impaired reduction of *Leishmania infantum* in PBMC ex vivo. The second section of this thesis contains, to our knowledge the first description of alterations in glomerular autophagy and inflammasome activation associated with immune-complex mediated glomerulonephritis severity in any species. This research will contribute to knowledge of the glomerular response to immune complex deposition, and elucidate potential avenues of intervention to limit long-term chronic renal damage. The third section of this thesis will describe the immunogenicity of one of a handful of second generation CanL vaccines, in multiple platforms, to determine the optimal means of administration. This research may lead, in part, to the approval of a novel polypeptide CanL vaccine, resulting in improved prevention of CanL and subsequent human transmission. This research as a whole is a significant contribution to the understanding of

the pathogenesis, immune response, and prevention of CanL and as a model of human infection. A comprehensive understanding of the basic mechanisms of VL immunity and pathology in a representative model is the optimal means of developing prevention and therapy for human leishmaniasis.

REFERENCES

1. **Esch, K.J. and C.A. Petersen**, *Transmission and epidemiology of zoonotic protozoal diseases of companion animals*. Clin Microbiol Rev, 2013. **26**(1): p. 58-85.
2. Association, A.P.P. *APPA national pet owners survey 2011-2012*. 2011 [cited 2012 April 5]; Available from: http://www.americanpetproducts.org/press_industrytrends.asp.
3. **Krause-Parello, C.A.**, *Pet Ownership and Older Women: The Relationships Among Loneliness, Pet Attachment Support, Human Social Support, and Depressed Mood*. Geriatr Nurs, 2012.
4. **Larsen, B.A. and F. Lingaas**, [*Dogs and health. A review of documented connections*]. Tidsskr Nor Laegeforen, 1997. **117**(30): p. 4375-9.
5. **McConnell, A.R., et al.**, *Friends with benefits: on the positive consequences of pet ownership*. J Pers Soc Psychol, 2011. **101**(6): p. 1239-52.
6. **Raina, P., et al.**, *Influence of companion animals on the physical and psychological health of older people: an analysis of a one-year longitudinal study*. J Am Geriatr Soc, 1999. **47**(3): p. 323-9.
7. **Ballweber, L.R., et al.**, *Giardiasis in dogs and cats: update on epidemiology and public health significance*. Trends Parasitol, 2010. **26**(4): p. 180-9.
8. **Jones, J.L., et al.**, *Risk factors for Toxoplasma gondii infection in the United States*. Clin Infect Dis, 2009. **49**(6): p. 878-84.
9. **Barr, S.C.**, *Canine Chagas' disease (American trypanosomiasis) in North America*. Vet Clin North Am Small Anim Pract, 2009. **39**(6): p. 1055-64, v-vi.

10. **Petersen, C.A.**, *Leishmaniasis, an emerging disease found in companion animals in the United States*. Top Companion Anim Med, 2009. **24**(4): p. 182-8.
11. **Chuang, Y.M., et al.**, *Disseminated cryptococcosis in HIV-uninfected patients*. Eur J Clin Microbiol Infect Dis, 2008. **27**(4): p. 307-10.
12. **Cribier, B.J. and R. Bakshi**, *Terbinafine in the treatment of onychomycosis: a review of its efficacy in high-risk populations and in patients with nondermatophyte infections*. Br J Dermatol, 2004. **150**(3): p. 414-20.
13. **Morsy, T.A., et al.**, *Natural infections of Leishmania major in domestic dogs from Alexandria, Egypt*. Am J Trop Med Hyg, 1987. **37**(1): p. 49-52.
14. **Akhavan, A.A., et al.**, *Dynamics of Leishmania infection rates in Rhombomys opimus (Rodentia: Gerbillinae) population of an endemic focus of zoonotic cutaneous leishmaniasis in Iran*. Bull Soc Pathol Exot, 2010. **103**(2): p. 84-9.
15. **Azizi, K., et al.**, *Gerbillus nanus (Rodentia: Muridae): a new reservoir host of Leishmania major*. Ann Trop Med Parasitol, 2011. **105**(6): p. 431-7.
16. **Ghawar, W., et al.**, *Leishmania major infection among Psammomys obesus and Meriones shawi: reservoirs of zoonotic cutaneous leishmaniasis in Sidi Bouzid (central Tunisia)*. Vector Borne Zoonotic Dis, 2011. **11**(12): p. 1561-8.
17. **Toumi, A., et al.**, *Temporal dynamics and impact of climate factors on the incidence of zoonotic cutaneous leishmaniasis in central Tunisia*. PLoS Negl Trop Dis, 2012. **6**(5): p. e1633.
18. **Wasserberg, G., et al.**, *The ecology of cutaneous leishmaniasis in Nizzana, Israel: infection patterns in the reservoir host, and epidemiological implications*. Int J Parasitol, 2002. **32**(2): p. 133-43.
19. **Yavar, R., et al.**, *Phlebotomus papatasi and Meriones libycus as the vector and reservoir host of cutaneous leishmaniasis in Qomrood District, Qom Province, central Iran*. Asian Pac J Trop Med, 2011. **4**(2): p. 97-100.
20. **Elbihari, S., A.H. Cheema, and A.M. el-Hassan**, *Leishmania infecting man and wild animals in Saudi Arabia. 4. Canine cutaneous leishmaniasis in the Eastern Province*. Trans R Soc Trop Med Hyg, 1987. **81**(6): p. 925-7.
21. **Gebre-Michael, T., et al.**, *The isolation of Leishmania tropica and L. aethiopica from Phlebotomus (Paraphlebotomus) species (Diptera: Psychodidae) in the Awash Valley, northeastern Ethiopia*. Trans R Soc Trop Med Hyg, 2004. **98**(1): p. 64-70.

22. **Lemma, W., et al.**, *A zoonotic focus of cutaneous leishmaniasis in Addis Ababa, Ethiopia*. Parasit Vectors, 2009. **2**(1): p. 60.
23. **Trainor, K.E., et al.**, *Eight cases of feline cutaneous leishmaniasis in Texas*. Vet Pathol, 2010. **47**(6): p. 1076-81.
24. **Wright, N.A., et al.**, *Cutaneous leishmaniasis in Texas: A northern spread of endemic areas*. J Am Acad Dermatol, 2008. **58**(4): p. 650-2.
25. **Kerr, S.F., C.P. McHugh, and N.O. Dronen, Jr.**, *Leishmaniasis in Texas: prevalence and seasonal transmission of Leishmania mexicana in Neotoma micropus*. Am J Trop Med Hyg, 1995. **53**(1): p. 73-7.
26. **Van Wynsberghe, N.R., et al.**, *Comparison of small mammal prevalence of Leishmania (Leishmania) mexicana in five foci of cutaneous leishmaniasis in the State of Campeche, Mexico*. Rev Inst Med Trop Sao Paulo, 2009. **51**(2): p. 87-94.
27. **Arjona-Jimenez, G., et al.**, *Prevalence of antibodies against three species of Leishmania (L. mexicana, L. braziliensis, L. infantum) and possible associated factors in dogs from Merida, Yucatan, Mexico*. Trans R Soc Trop Med Hyg, 2012. **106**(4): p. 252-8.
28. **Longoni, S.S., et al.**, *Detection of different Leishmania spp. and Trypanosoma cruzi antibodies in cats from the Yucatan Peninsula (Mexico) using an iron superoxide dismutase excreted as antigen*. Comp Immunol Microbiol Infect Dis, 2012. **35**(5): p. 469-76.
29. **Telleria, J., et al.**, *Putative reservoirs of Leishmania amazonensis in a sub-andean focus of Bolivia identified by kDNA-polymerase chain reaction*. Mem Inst Oswaldo Cruz, 1999. **94**(1): p. 5-6.
30. **Tolezano, J.E., et al.**, *The first records of Leishmania (Leishmania) amazonensis in dogs (Canis familiaris) diagnosed clinically as having canine visceral leishmaniasis from Aracatuba County, Sao Paulo State, Brazil*. Vet Parasitol, 2007. **149**(3-4): p. 280-4.
31. **Guessous-Idrissi, N., et al.**, *Short report: Leishmania tropica: etiologic agent of a case of canine visceral leishmaniasis in northern Morocco*. Am J Trop Med Hyg, 1997. **57**(2): p. 172-3.
32. **Dereure, J., et al.**, *Leishmania tropica in Morocco: infection in dogs*. Trans R Soc Trop Med Hyg, 1991. **85**(5): p. 595.

33. **Jacobson, R.L., et al.**, *Outbreak of cutaneous leishmaniasis in northern Israel*. J Infect Dis, 2003. **188**(7): p. 1065-73.
34. **Talmi-Frank, D., et al.**, *Leishmania tropica infection in golden jackals and red foxes, Israel*. Emerg Infect Dis, 2010. **16**(12): p. 1973-5.
35. **Mohebbali, M., et al.**, *Epidemiological aspects of canine visceral leishmaniasis in the Islamic Republic of Iran*. Vet Parasitol, 2005. **129**(3-4): p. 243-51.
36. **Schallig, H.D., et al.**, *Didelphis marsupialis (common opossum): a potential reservoir host for zoonotic leishmaniasis in the metropolitan region of Belo Horizonte (Minas Gerais, Brazil)*. Vector Borne Zoonotic Dis, 2007. **7**(3): p. 387-93.
37. **Quaresma, P.F., et al.**, *Wild, synanthropic and domestic hosts of Leishmania in an endemic area of cutaneous leishmaniasis in Minas Gerais State, Brazil*. Trans R Soc Trop Med Hyg, 2011. **105**(10): p. 579-85.
38. **Aguilar, C.M., et al.**, *Zoonotic cutaneous leishmaniasis due to Leishmania (Viannia) braziliensis associated with domestic animals in Venezuela and Brazil*. Mem Inst Oswaldo Cruz, 1989. **84**(1): p. 19-28.
39. **Dantas-Torres, F.**, *The role of dogs as reservoirs of Leishmania parasites, with emphasis on Leishmania (Leishmania) infantum and Leishmania (Viannia) braziliensis*. Vet Parasitol, 2007. **149**(3-4): p. 139-46.
40. **Christensen, H.A., et al.**, *Hosts of sandfly vectors of Leishmania braziliensis guyanensis in the central Amazon of Brazil*. Am J Trop Med Hyg, 1982. **31**(2): p. 239-42.
41. **Santaella, J., et al.**, *Leishmania (Viannia) infection in the domestic dog in Chaparral, Colombia*. Am J Trop Med Hyg, 2011. **84**(5): p. 674-80.
42. **Llanos-Cuentas, E.A., et al.**, *Natural infections of Leishmania peruviana in animals in the Peruvian Andes*. Trans R Soc Trop Med Hyg, 1999. **93**(1): p. 15-20.
43. **Lainson, R., et al.**, *Leishmania (Viannia) shawi sp. n., a parasite of monkeys, sloths and procyonids in Amazonian Brazil*. Ann Parasitol Hum Comp, 1989. **64**(3): p. 200-7.
44. **Lainson, R., et al.**, *Further observations on Lutzomyia ubiquitalis (Psychodidae: Phlebotominae), the sandfly vector of Leishmania (Viannia) lainsoni*. Mem Inst Oswaldo Cruz, 1992. **87**(3): p. 437-9.

45. **Lainson, R. and J.J. Shaw**, *Leishmania (Viannia) naiffi sp. n., a parasite of the armadillo, Dasypus novemcinctus (L.) in Amazonian Brazil*. Ann Parasitol Hum Comp, 1989. **64**(1): p. 3-9.
46. **Bonfante-Garrido, R., et al.**, *Natural infection of cats with Leishmania in Barquisimeto, Venezuela*. Trans R Soc Trop Med Hyg, 1991. **85**(1): p. 53.
47. **Dereure, J., et al.**, [*Leishmaniasis in Ecuador. 4. Natural infestation of the dog by Leishmania panamensis*]. Ann Soc Belg Med Trop, 1994. **74**(1): p. 29-33.
48. **Herrer, A. and H.A. Christensen**, *Leishmania braziliensis in the Panamanian two-toed sloth, Choloepus hoffmanni*. Am J Trop Med Hyg, 1980. **29**(6): p. 1196-200.
49. **Thatcher, V.E., C. Eisenmann, and M. Hertig**, *A natural infection of Leishmania in the kinkajou, Potos flavus, in Panama*. J Parasitol, 1965. **51**(6): p. 1022-3.
50. **Velez, I.D., et al.**, *An epidemic outbreak of canine cutaneous leishmaniasis in Colombia caused by Leishmania braziliensis and Leishmania panamensis*. Am J Trop Med Hyg, 2012. **86**(5): p. 807-11.
51. **Herrer, A. and H.A. Christensen**, *Natural cutaneous leishmaniasis among dogs in Panama*. Am J Trop Med Hyg, 1976. **25**(1): p. 59-63.
52. **Bhattarai, N.R., et al.**, *Domestic animals and epidemiology of visceral leishmaniasis, Nepal*. Emerg Infect Dis, 2010. **16**(2): p. 231-7.
53. **Dereure, J., et al.**, *Visceral leishmaniasis in eastern Sudan: parasite identification in humans and dogs; host-parasite relationships*. Microbes Infect, 2003. **5**(12): p. 1103-8.
54. **Kalayou, S., et al.**, *Serological evidence of Leishmania donovani infection in apparently healthy dogs using direct agglutination test (DAT) and rk39 dipstick tests in Kafta Humera, north-west Ethiopia*. Transbound Emerg Dis, 2011. **58**(3): p. 255-62.
55. **Sharma, N.L., et al.**, *The rK39 immunochromatographic dipstick testing: a study for K39 seroprevalence in dogs and human leishmaniasis patients for possible animal reservoir of cutaneous and visceral leishmaniasis in endemic focus of Satluj river valley of Himachal Pradesh (India)*. Indian J Dermatol Venereol Leprol, 2009. **75**(1): p. 52-5.
56. **Gramiccia, M. and L. Gradoni**, *The current status of zoonotic leishmaniases and approaches to disease control*. Int J Parasitol, 2005. **35**(11-12): p. 1169-80.

57. **Vides, J.P., et al.**, *Leishmania chagasi infection in cats with dermatologic lesions from an endemic area of visceral leishmaniosis in Brazil*. *Vet Parasitol*, 2011. **178**(1-2): p. 22-8.
58. **Lima, I.D., et al.**, *Leishmania infantum chagasi in northeastern Brazil: asymptomatic infection at the urban perimeter*. *Am J Trop Med Hyg*, 2012. **86**(1): p. 99-107.
59. **Coura-Vital, W., et al.**, *Prevalence and factors associated with Leishmania infantum infection of dogs from an urban area of Brazil as identified by molecular methods*. *PLoS Negl Trop Dis*, 2011. **5**(8): p. e1291.
60. **Falqueto, A., et al.**, *Cross-sectional and longitudinal epidemiologic surveys of human and canine Leishmania infantum visceral infections in an endemic rural area of southeast Brazil (Pancas, Espirito Santo)*. *Am J Trop Med Hyg*, 2009. **80**(4): p. 559-65.
61. **Esch, K.J., et al.**, *Preventing zoonotic canine leishmaniasis in northeastern Brazil: pet attachment and adoption of community leishmania prevention*. *Am J Trop Med Hyg*, 2012. **87**(5): p. 822-31.
62. **Martin-Sanchez, J., et al.**, *Canine leishmaniasis in southeastern Spain*. *Emerg Infect Dis*, 2009. **15**(5): p. 795-8.
63. **Cortes, S., et al.**, *Risk factors for canine leishmaniasis in an endemic Mediterranean region*. *Vet Parasitol*, 2012.
64. **Tabar, M.D., et al.**, *Vector-borne infections in cats: molecular study in Barcelona area (Spain)*. *Vet Parasitol*, 2008. **151**(2-4): p. 332-6.
65. **Molina, R., et al.**, *The hare (Lepus granatensis) as potential sylvatic reservoir of Leishmania infantum in Spain*. *Vet Parasitol*, 2012.
66. **Tenorio Mda, S., et al.**, *Visceral leishmaniasis in a captive crab-eating fox Cerdocyon thous*. *J Zoo Wildl Med*, 2011. **42**(4): p. 608-16.
67. **Jusi, M.M., et al.**, *Molecular and serological detection of Leishmania spp. in captive wild animals from Ilha Solteira, SP, Brazil*. *Rev Bras Parasitol Vet*, 2011. **20**(3): p. 219-22.
68. **Tzamouranis, N., et al.**, *Leishmaniasis in Greece I. Isolation and identification of the parasite causing human and canine visceral leishmaniasis*. *Ann Trop Med Parasitol*, 1984. **78**(4): p. 363-8.

69. **Maia, C., et al.**, *Feline Leishmania infection in a canine leishmaniasis endemic region, Portugal*. *Vet Parasitol*, 2010. **174**(3-4): p. 336-40.
70. **Cardoso, L., et al.**, *Low seroprevalence of Leishmania infantum infection in cats from northern Portugal based on DAT and ELISA*. *Vet Parasitol*, 2010. **174**(1-2): p. 37-42.
71. **Sherry, K., et al.**, *A serological and molecular study of Leishmania infantum infection in cats from the Island of Ibiza (Spain)*. *Vector Borne Zoonotic Dis*, 2011. **11**(3): p. 239-45.
72. **Hatam, G.R., et al.**, *First report of natural infection in cats with Leishmania infantum in Iran*. *Vector Borne Zoonotic Dis*, 2010. **10**(3): p. 313-6.
73. **Nasereddin, A., H. Salant, and Z. Abdeen**, *Feline leishmaniasis in Jerusalem: serological investigation*. *Vet Parasitol*, 2008. **158**(4): p. 364-9.
74. **Coelho, W.M., et al.**, *Seroepidemiology of Toxoplasma gondii, Neospora caninum, and Leishmania spp. infections and risk factors for cats from Brazil*. *Parasitol Res*, 2011. **109**(4): p. 1009-13.
75. **Cardoso, L., C. Mendao, and L. Madeira de Carvalho**, *Prevalence of Dirofilaria immitis, Ehrlichia canis, Borrelia burgdorferi sensu lato, Anaplasma spp. and Leishmania infantum in apparently healthy and CVBD-suspect dogs in Portugal--a national serological study*. *Parasit Vectors*, 2012. **5**: p. 62.
76. **Athanasiou, L.V., et al.**, *A cross-sectional sero-epidemiological study of canine leishmaniasis in Greek mainland*. *Acta Trop*, 2012. **122**(3): p. 291-5.
77. **Kovalenko, D.A., et al.**, *[Human and canine visceral leishmaniasis in the Papsky District, Namangan Region, Uzbekistan: seroepidemiological and seroepizootological surveys]*. *Med Parazitol (Mosk)*, 2011(3): p. 32-7.
78. **Shang, L.M., et al.**, *The prevalence of canine Leishmania infantum infection in Sichuan Province, southwestern China detected by real time PCR*. *Parasit Vectors*, 2011. **4**(1): p. 173.
79. **Sousa, S., et al.**, *Seroepidemiological survey of Leishmania infantum infection in dogs from northeastern Portugal*. *Acta Trop*, 2011. **120**(1-2): p. 82-7.
80. **Faye, B., et al.**, *Canine visceral leishmaniasis caused by Leishmania infantum in Senegal: risk of emergence in humans?* *Microbes Infect*, 2010. **12**(14-15): p. 1219-25.

81. **Baldelli, R., et al.**, *A new stable focus of canine leishmaniasis in northern Italy.* *Parassitologia*, 2001. **43**(4): p. 151-3.
82. **Ozensoy Toz, S., et al.**, *Serological and entomological survey of zoonotic visceral leishmaniasis in Denizli Province, Aegean Region, Turkey.* *New Microbiol*, 2009. **32**(1): p. 93-100.
83. **Lemesre, J.L., et al.**, *Long-lasting protection against canine visceral leishmaniasis using the LiESAp-MDP vaccine in endemic areas of France: double-blind randomised efficacy field trial.* *Vaccine*, 2007. **25**(21): p. 4223-34.
84. **Magill, A.J., et al.**, *Visceral infection caused by Leishmania tropica in veterans of Operation Desert Storm.* *N Engl J Med*, 1993. **328**(19): p. 1383-7.
85. **Ives, A., et al.**, *Leishmania RNA virus controls the severity of mucocutaneous leishmaniasis.* *Science*, 2011. **331**(6018): p. 775-8.
86. **Daneshbod, Y., et al.**, *Clinical, histopathologic, and cytologic diagnosis of mucosal leishmaniasis and literature review.* *Arch Pathol Lab Med*, 2011. **135**(4): p. 478-82.
87. **Herwaldt, B.L.**, *Leishmaniasis.* *Lancet*, 1999. **354**(9185): p. 1191-9.
88. **Herwaldt, B.L., B.A. Arana, and T.R. Navin**, *The natural history of cutaneous leishmaniasis in Guatemala.* *J Infect Dis*, 1992. **165**(3): p. 518-27.
89. **Dowlati, Y.**, *Cutaneous leishmaniasis: clinical aspect.* *Clin Dermatol*, 1996. **14**(5): p. 425-31.
90. **Machado, P., et al.**, *Failure of early treatment of cutaneous leishmaniasis in preventing the development of an ulcer.* *Clin Infect Dis*, 2002. **34**(12): p. E69-73.
91. **Magill, A.J.**, *Cutaneous leishmaniasis in the returning traveler.* *Infect Dis Clin North Am*, 2005. **19**(1): p. 241-66, x-xi.
92. **David, C.V. and N. Craft**, *Cutaneous and mucocutaneous leishmaniasis.* *Dermatol Ther*, 2009. **22**(6): p. 491-502.
93. **Sinha, S., et al.**, *Diffuse cutaneous leishmaniasis associated with the immune reconstitution inflammatory syndrome.* *Int J Dermatol*, 2008. **47**(12): p. 1263-70.
94. **Convit, J. and F. Kerdel-Vegas**, *Disseminated Cutaneous Leishmaniasis; Inoculation To Laboratory Animals, Electron Microscopy And Fluorescent Antibodies Studies.* *Arch Dermatol*, 1965. **91**: p. 439-47.

95. **Convit, J., O. Reyes, and F. Kerdel**, *Disseminated anergic American leishmaniasis; report of three cases of a type clinically resembling lepromatous leprosy*. *AMA Arch Derm*, 1957. **76**(2): p. 213-7.
96. **Petersen, E.A., et al.**, *Specific inhibition of lymphocyte-proliferation responses by adherent suppressor cells in diffuse cutaneous leishmaniasis*. *N Engl J Med*, 1982. **306**(7): p. 387-92.
97. **al-Gindan, Y., et al.**, *Dissemination in cutaneous leishmaniasis. 3. Lymph node involvement*. *Int J Dermatol*, 1989. **28**(4): p. 248-54.
98. **Machado-Coelho, G.L., et al.**, *Risk factors for mucosal manifestation of American cutaneous leishmaniasis*. *Trans R Soc Trop Med Hyg*, 2005. **99**(1): p. 55-61.
99. **Weigle, K. and N.G. Saravia**, *Natural history, clinical evolution, and the host-parasite interaction in New World cutaneous Leishmaniasis*. *Clin Dermatol*, 1996. **14**(5): p. 433-50.
100. **Ahluwalia, S., et al.**, *Mucocutaneous leishmaniasis: an imported infection among travellers to central and South America*. *Bmj*, 2004. **329**(7470): p. 842-4.
101. **Sinha, P.K., K. Pandey, and S.K. Bhattacharya**, *Diagnosis & management of Leishmania/HIV co-infection*. *Indian J Med Res*, 2005. **121**(4): p. 407-14.
102. **Franke, E.D., et al.**, *Efficacy and toxicity of sodium stibogluconate for mucosal leishmaniasis*. *Ann Intern Med*, 1990. **113**(12): p. 934-40.
103. **Dhingra, K.K., et al.**, *Morphological findings in bone marrow biopsy and aspirate smears of visceral Kala Azar: a review*. *Indian J Pathol Microbiol*, 2010. **53**(1): p. 96-100.
104. **Daher, E.F., et al.**, *Clinical presentation and renal evaluation of human visceral leishmaniasis (kala-azar): a retrospective study of 57 patients in Brazil*. *Braz J Infect Dis*, 2008. **12**(4): p. 329-32.
105. **Baneth, G., et al.**, *Canine leishmaniosis - new concepts and insights on an expanding zoonosis: part one*. *Trends Parasitol*, 2008. **24**(7): p. 324-30.
106. **Solano-Gallego, L., et al.**, *Directions for the diagnosis, clinical staging, treatment and prevention of canine leishmaniosis*. *Vet Parasitol*, 2009. **165**(1-2): p. 1-18.

107. **Koutinas, A.F., et al.**, *Clinical considerations on canine visceral leishmaniasis in Greece: a retrospective study of 158 cases (1989-1996)*. J Am Anim Hosp Assoc, 1999. **35**(5): p. 376-83.
108. **Ordeix, L., et al.**, *Papular dermatitis due to Leishmania spp. infection in dogs with parasite-specific cellular immune responses*. Vet Dermatol, 2005. **16**(3): p. 187-91.
109. **Costa, F.A., et al.**, *Histopathologic patterns of nephropathy in naturally acquired canine visceral leishmaniasis*. Vet Pathol, 2003. **40**(6): p. 677-84.
110. **Zatelli, A., et al.**, *Glomerular lesions in dogs infected with Leishmania organisms*. Am J Vet Res, 2003. **64**(5): p. 558-61.
111. **Peters, N.C., et al.**, *In vivo imaging reveals an essential role for neutrophils in leishmaniasis transmitted by sand flies*. Science, 2008. **321**(5891): p. 970-4.
112. **Aga, E., et al.**, *Inhibition of the spontaneous apoptosis of neutrophil granulocytes by the intracellular parasite Leishmania major*. J Immunol, 2002. **169**(2): p. 898-905.
113. **Laufs, H., et al.**, *Intracellular survival of Leishmania major in neutrophil granulocytes after uptake in the absence of heat-labile serum factors*. Infect Immun, 2002. **70**(2): p. 826-35.
114. **Boggiatto, P.M., et al.**, *Altered dendritic cell phenotype in response to Leishmania amazonensis amastigote infection is mediated by MAP kinase, ERK*. Am J Pathol, 2009. **174**(5): p. 1818-26.
115. **Sibley, L.D.**, *Invasion and intracellular survival by protozoan parasites*. Immunol Rev, 2011. **240**(1): p. 72-91.
116. **Ueno, N., et al.**, *Differences in human macrophage receptor usage, lysosomal fusion kinetics and survival between logarithmic and metacyclic Leishmania infantum chagasi promastigotes*. Cell Microbiol, 2009. **11**(12): p. 1827-41.
117. **Lodge, R. and A. Descoteaux**, *Leishmania invasion and phagosome biogenesis*. Subcell Biochem, 2008. **47**: p. 174-81.
118. **Sacks, D.L.**, *Leishmania-sand fly interactions controlling species-specific vector competence*. Cell Microbiol, 2001. **3**(4): p. 189-96.
119. **Desjardins, M. and A. Descoteaux**, *Inhibition of phagolysosomal biogenesis by the Leishmania lipophosphoglycan*. J Exp Med, 1997. **185**(12): p. 2061-8.

120. **Huynh, C., D.L. Sacks, and N.W. Andrews,** *A Leishmania amazonensis ZIP family iron transporter is essential for parasite replication within macrophage phagolysosomes.* J Exp Med, 2006. **203**(10): p. 2363-75.
121. **Ehrchen, J.M., et al.,** *Keratinocytes determine Th1 immunity during early experimental leishmaniasis.* PLoS Pathog, 2010. **6**(4): p. e1000871.
122. **Ribeiro-Gomes, F.L., et al.,** *Efficient capture of infected neutrophils by dendritic cells in the skin inhibits the early anti-leishmania response.* PLoS Pathog, 2012. **8**(2): p. e1002536.
123. **Khamesipour, A., et al.,** *Leishmanization: use of an old method for evaluation of candidate vaccines against leishmaniasis.* Vaccine, 2005. **23**(28): p. 3642-8.
124. **Nadim, A., et al.,** *Effectiveness of leishmanization in the control of cutaneous leishmaniasis.* Bull Soc Pathol Exot Filiales, 1983. **76**(4): p. 377-83.
125. **Khamesipour, A., et al.,** *Treatment of cutaneous lesion of 20 years' duration caused by leishmanization.* Indian J Dermatol, 2012. **57**(2): p. 123-5.
126. **Hosseini, S.M., G.R. Hatam, and S. Ardehali,** *Characterization of Leishmania isolated from unhealed lesions caused by leishmanization.* East Mediterr Health J, 2005. **11**(1-2): p. 240-3.
127. **Duthie, M.S., et al.,** *The development and clinical evaluation of second-generation leishmaniasis vaccines.* Vaccine, 2012. **30**(2): p. 134-41.
128. **Gomes, R., et al.,** *KSAC, a defined Leishmania antigen, plus adjuvant protects against the virulence of L. major transmitted by its natural vector Phlebotomus duboscqi.* PLoS Negl Trop Dis, 2012. **6**(4): p. e1610.
129. **Goto, Y., et al.,** *KSAC, the first defined polyprotein vaccine candidate for visceral leishmaniasis.* Clin Vaccine Immunol, 2011. **18**(7): p. 1118-24.
130. **Peters, N.C., et al.,** *Evaluation of recombinant Leishmania polyprotein plus glucopyranosyl lipid A stable emulsion vaccines against sand fly-transmitted Leishmania major in C57BL/6 mice.* J Immunol, 2012. **189**(10): p. 4832-41.
131. **Gradoni, L., et al.,** *Failure of a multi-subunit recombinant leishmanial vaccine (MML) to protect dogs from Leishmania infantum infection and to prevent disease progression in infected animals.* Vaccine, 2005. **23**(45): p. 5245-51.

132. **Selvapandiyan, A., et al.**, *Immunity to visceral leishmaniasis using genetically defined live-attenuated parasites*. J Trop Med, 2012. **2012**: p. 631460.
133. **Selvapandiyan, A., et al.**, *Intracellular replication-deficient Leishmania donovani induces long lasting protective immunity against visceral leishmaniasis*. J Immunol, 2009. **183**(3): p. 1813-20.
134. **da Silva, V.O., et al.**, *A phase III trial of efficacy of the FML-vaccine against canine kala-azar in an endemic area of Brazil (Sao Goncalo do Amaranto, RN)*. Vaccine, 2000. **19**(9-10): p. 1082-92.
135. **Parra, L.E., et al.**, *Safety trial using the Leishmune vaccine against canine visceral leishmaniasis in Brazil*. Vaccine, 2007. **25**(12): p. 2180-6.
136. (WHO), W.H.O., *Leishmaniasis: epidemiology and access to medicines*. 2012, WHO: Geneva.
137. **Gonzalez, C., et al.**, *Climate change and risk of leishmaniasis in north america: predictions from ecological niche models of vector and reservoir species*. PLoS Negl Trop Dis, 2010. **4**(1): p. e585.
138. **Faulde, M., et al.**, *Zoonotic cutaneous leishmaniasis outbreak in Mazar-e Sharif, northern Afghanistan: an epidemiological evaluation*. Int J Med Microbiol, 2008. **298**(5-6): p. 543-50.
139. **Barnes, J.C., O. Stanley, and T.M. Craig**, *Diffuse cutaneous leishmaniasis in a cat*. J Am Vet Med Assoc, 1993. **202**(3): p. 416-8.
140. **Sellon, R.K., et al.**, *Endemic visceral leishmaniasis in a dog from Texas*. J Vet Intern Med, 1993. **7**(1): p. 16-9.
141. **Craig, T.M., et al.**, *Dermal leishmaniasis in a Texas cat*. Am J Trop Med Hyg, 1986. **35**(6): p. 1100-2.
142. **Barrett, T.V. and M.S. Senra**, *Leishmaniasis in Manaus, Brazil*. Parasitol Today, 1989. **5**(8): p. 255-7.
143. **Desjeux, P.**, *Worldwide increasing risk factors for leishmaniasis*. Med Microbiol Immunol, 2001. **190**(1-2): p. 77-9.
144. **Jirmanus, L., et al.**, *Epidemiological and clinical changes in American tegumentary leishmaniasis in an area of Leishmania (Viannia) braziliensis transmission over a 20-year period*. Am J Trop Med Hyg, 2012. **86**(3): p. 426-33.

145. **Votypka, J., et al.**, *Risk factors for cutaneous leishmaniasis in Cukurova region, Turkey*. *Trans R Soc Trop Med Hyg*, 2012. **106**(3): p. 186-90.
146. **Reithinger, R., M. Mohsen, and T. Leslie**, *Risk factors for anthroponotic cutaneous Leishmaniasis at the household level in Kabul, Afghanistan*. *PLoS Negl Trop Dis*, 2010. **4**(3): p. e639.
147. **Morrone, A., et al.**, *Epidemiological and geographical aspects of leishmaniasis in Tigray, northern Ethiopia: a retrospective analysis of medical records, 2005-2008*. *Trans R Soc Trop Med Hyg*, 2011. **105**(5): p. 273-80.
148. **Pedrosa Fde, A. and R.A. Ximenes**, *Sociodemographic and environmental risk factors for American cutaneous leishmaniasis (ACL) in the State of Alagoas, Brazil*. *Am J Trop Med Hyg*, 2009. **81**(2): p. 195-201.
149. **Dahroug, M.A., et al.**, *Leishmania chagasi in captive wild felids in Brazil*. *Trans R Soc Trop Med Hyg*, 2010. **104**(1): p. 73-4.
150. **Michel, G., et al.**, *Importance of worldwide asymptomatic carriers of Leishmania infantum (L. chagasi) in human*. *Acta Trop*, 2011. **119**(2-3): p. 69-75.
151. **Boggiatto, P.M., et al.**, *Transplacental transmission of Leishmania infantum as a means for continued disease incidence in North America*. *PLoS Negl Trop Dis*, 2011. **5**(4): p. e1019.
152. **Dujardin, J.C., et al.**, *Spread of vector-borne diseases and neglect of Leishmaniasis, Europe*. *Emerg Infect Dis*, 2008. **14**(7): p. 1013-8.
153. **Galvez, R., et al.**, *Emerging trends in the seroprevalence of canine leishmaniasis in the Madrid region (central Spain)*. *Vet Parasitol*, 2010. **169**(3-4): p. 327-34.
154. **Alvar, J., et al.**, *Leishmaniasis Worldwide and Global Estimates of Its Incidence*. *PLoS One*, 2012. **7**(5): p. e35671.
155. **de Almeida, A.S., A. Medronho Rde, and G.L. Werneck**, *Identification of risk areas for visceral leishmaniasis in Teresina, Piaui State, Brazil*. *Am J Trop Med Hyg*, 2011. **84**(5): p. 681-7.
156. **Harhay, M.O., et al.**, *Who is a typical patient with visceral leishmaniasis? Characterizing the demographic and nutritional profile of patients in Brazil, East Africa, and South Asia*. *Am J Trop Med Hyg*, 2011. **84**(4): p. 543-50.

157. **Pagliano, P., et al.**, *Visceral leishmaniasis in pregnancy: a case series and a systematic review of the literature*. J Antimicrob Chemother, 2005. **55**(2): p. 229-33.
158. **Tesh, R.B.**, *Control of zoonotic visceral leishmaniasis: is it time to change strategies?* Am J Trop Med Hyg, 1995. **52**(3): p. 287-92.
159. **Costa, C.H.**, *How effective is dog culling in controlling zoonotic visceral leishmaniasis? A critical evaluation of the science, politics and ethics behind this public health policy*. Rev Soc Bras Med Trop, 2011. **44**(2): p. 232-42.
160. **Aresu, L., et al.**, *Membranoproliferative glomerulonephritis type III in a simultaneous infection of Leishmania infantum and Dirofilaria immitis in a dog*. J Vet Diagn Invest, 2007. **19**(5): p. 569-72.
161. **Cortese, L., et al.**, *Prevalence of anti-platelet antibodies in dogs naturally co-infected by Leishmania infantum and Ehrlichia canis*. Vet J, 2011. **188**(1): p. 118-21.
162. **Blackwell, J.M., et al.**, *Genetics and visceral leishmaniasis: of mice and man*. Parasite Immunol, 2009. **31**(5): p. 254-66.
163. **Soto, J., et al.**, *Efficacy of permethrin-impregnated uniforms in the prevention of malaria and leishmaniasis in Colombian soldiers*. Clin Infect Dis, 1995. **21**(3): p. 599-602.
164. **Rojas, C.A., et al.**, *A multifaceted intervention to prevent American cutaneous leishmaniasis in Colombia: results of a group-randomized trial*. Biomedica, 2006. **26** Suppl 1: p. 152-66.
165. **Mutinga, M.J., et al.**, *A bioassay to evaluate the efficacy of permethrin-impregnated screens used against phlebotomine sandflies (Diptera: Psychodidae) in Baringo District of Kenya*. East Afr Med J, 1993. **70**(3): p. 168-70.
166. **Harhay, M.O., et al.**, *Urban parasitology: visceral leishmaniasis in Brazil*. Trends Parasitol, 2011. **27**(9): p. 403-9.
167. **Courtenay, O., et al.**, *A long-lasting topical deltamethrin treatment to protect dogs against visceral leishmaniasis*. Med Vet Entomol, 2009. **23**(3): p. 245-56.
168. **Quinnell, R.J. and O. Courtenay**, *Transmission, reservoir hosts and control of zoonotic visceral leishmaniasis*. Parasitology, 2009. **136**(14): p. 1915-34.

169. **Moura, G.S., et al.**, *Factors associated with asymptomatic infection in family members and neighbors of patients with visceral leishmaniasis*. Cad Saude Publica, 2012. **28**(12): p. 2306-14.
170. **Yang, Z., D.M. Mosser, and X. Zhang**, *Activation of the MAPK, ERK, following Leishmania amazonensis infection of macrophages*. J Immunol, 2007. **178**(2): p. 1077-85.
171. **Gibson-Corley, K.N., et al.**, *A deficiency in the B cell response of C57BL/6 mice correlates with loss of macrophage-mediated killing of Leishmania amazonensis*. Int J Parasitol, 2010. **40**(2): p. 157-61.

CHAPTER 2

**PD-1-MEDIATED T CELL EXHAUSTION DURING VISCERAL
LEISHMANIASIS**

Kevin J. Esch, Rachel Juelsgaard, Pedro A. Martinez, Douglas E. Jones, Christine A.

Petersen

Department of Veterinary Pathology, College of Veterinary Medicine, Iowa State University,
Ames, IA

A journal article to be re-submitted to the Journal of Immunology

ABSTRACT

There is currently no licensed vaccine for visceral leishmaniasis (VL), and chemotherapy has thus far had frequent toxicity, with a high rate of VL recrudescence. Control of *Leishmania infantum* infection is dependent upon Th1 CD4⁺ T cells to promote macrophage intracellular clearance of parasites. Deficient CD4⁺ T cell effector responses during clinical visceral leishmaniasis (VL) are associated with elevated production of IL-10, TGF- β , and IL-4. In a naturally occurring canine model of VL, we characterized occurrence of CD4⁺ and CD8⁺ T cell exhaustion as a significant stepwise loss of antigen-specific proliferation and IFN γ production, corresponding to increasing VL symptomatology. Exhaustion was associated with a four-fold increase in the population of T cells with surface expression of Programmed Death 1 (PD-1) between control and symptomatic populations. Exhausted populations of CD8⁺ T cells, and to a lesser extent CD4⁺ T cells, were present

prior to the onset of clinical VL. Exhausted T cells did not undergo significant apoptosis *ex vivo* with antigen stimulation, even with recovery of proliferation. Antibody block of PD-1 ligand, B7.H1, promoted return of CD4⁺ and CD8⁺ T cell function and dramatically increased reactive oxygen species production in co-cultured monocyte-derived phagocytes. As a result, these phagocytes had decreased parasite load. These results demonstrate that PD-1-mediated exhaustion during VL influences macrophage reactive oxygen intermediate production and improves the ability of phagocytes to clear parasites from cells isolated from animals with natural infection. Influencing PD-1/B7.H1-mediated negative regulation of the CD4⁺ Th1 response has potential to significantly improve therapeutic outcomes for visceral leishmaniasis, limiting immune pathology, and slowing the onset of symptomatic disease.

INTRODUCTION

Zoonotic visceral leishmaniasis (VL) is a fatal systemic illness, resulting in 500,000 annual new human cases and approximately 50,000 deaths per year. *Leishmania infantum*, a vector-borne, protozoan parasite, is the causative agent of VL in the New World. Natural hosts of *L. infantum* include dogs and humans [1]. Asymptomatic status depends on a T helper 1 protective response during chronic VL. In patients that progress to disease, the immune response was skewed toward TGF- β , IL-10 or IL-4-producing Th2 and/or T regulatory cells [2, 3]. We previously demonstrated that as dogs progressed to clinical VL, there was impaired CD4⁺ T cell proliferation and IFN γ production *ex-vivo* in response to *L. infantum* antigen with increased production of IL-10, similar to human VL [4]. T cell exhaustion has been defined as antigen-specific effector T cell dysfunction characterized by sustained expression of inhibitory receptors including PD-1 and decreased effector cytokine

production [5]. Exhaustion of CD8+ T cells has been identified in chronic viral infections and parasitic disease including toxoplasmosis and cutaneous leishmaniasis [6-8]. Here we report, for the first time, concurrent CD4+ and CD8+ T cell exhaustion in VL. This exhaustion was mediated by PD-1 surface expression on CD4+ and CD8+ T cells, associated with progressive disease.

T cell exhaustion progresses incrementally, and can eventually result in the clonal deletion of CD8+ T cells during chronic viral infection [9]. Reports of chronic infection indicate that populations of exhausted T cells are maintained by TCR stimulation with cognate antigen, even in the absence of IL-7 and IL-15, with low levels of proliferation [10]. Additional studies during experimental *Leishmania major* infection indicate that antigen-experienced T cells preferentially respond to presented antigen to the exclusion of naïve T cell populations [11]. Research into T cell homeostasis utilizing adoptively transferred ovalbumin (OVA)-specific CD4+ T cells into OVA transgenic mice with continual antigen exposure demonstrate a population of tolerant T cells that survive a contraction phase and are quiescent but can maintain tolerance in the absence of clonal deletion [12]. In this study we evaluated apoptosis in CD4+ and CD8+ T cells from asymptomatic and symptomatic dogs infected with *Leishmania infantum*, demonstrating the presence of an exhausted T cell population which does not proliferate or undergo apoptosis in response to antigen. The CD4+ and CD8+ populations were responsive to blockage of PD-1/B7.H1, increasing proliferative capacity, indicating that this effector memory population had not been clonally deleted.

Previous reports demonstrated that phagocyte-based reactive oxygen (ROI) and nitrogen intermediates (RNI) were critical for removal of intracellular *Leishmania* [13, 14]. Production of ROI and RNI required T cell IFN- γ production [15]. In this study, blockade of

B7.H1 resulted in recovery of Th1-effector function, recovery of phagocyte superoxide production and decreased parasite load in peripheral blood-derived monocytes from naturally-infected dogs. These novel findings link rescue from CD4+ T cell exhaustion to improved monocyte function through augmented of superoxide production and removal of intracellular *L. infantum*.

MATERIALS AND METHODS

Sample Population and Study Enrollment – Dogs were enrolled by serology, clinical signs, and quantitative Real Time-PCR (qRT-PCR) positivity as previously described [4]. Dogs were 2 to 7 years old, and had complete veterinary care. Twenty milliliters of blood was collected from each dog at intervals greater than 2 weeks. Procedures were performed with approval from Iowa State University IACUC.

Clinical Staging of Study Animals - Study animals were assessed via physical and laboratory examination and *L. infantum* diagnostics (*L. infantum* kinetoplast DNA (kDNA)-specific qPCR, IFAT, and K39/22 (DPP, Chembio, Medford, NY) serologic analysis). Infected animals were classified as: 1) asymptomatic- no clinical signs, qPCR positive, and IFAT <1:256, 2) symptomatic- two or more signs of leishmaniasis (lymphadenomegaly, palpable liver or spleen, alterations in hepatic or renal enzymes), IFAT \geq 1:256, and qPCR positive.

Sample Handling and PBMC Isolation - Whole blood samples were separated into PBMC as previously described [4]. Whole blood samples collected in heparin-containing tubes were diluted 1:1 with 1x Hank's Buffered Salt Solution (Cellgro, Manassas, VA) and 25mM

HEPES . Diluted whole blood was centrifuged at 800 ref (Eppendorf, Hauppauge, NY) for 30 minutes at room temperature through Ficoll/Histopaque 1077 (Sigma Aldrich, St. Louis, MO) as previously described [4]. PBMC were counted with an automated cell counter (Beckman Coulter, Brea, CA). PBMC were washed twice in phosphate-buffered saline (PBS) and suspended in complete medium (CTCM) (RPMI 1640 supplemented with 10% fetal bovine serum, 100 U/ml penicillin, 100 µg/ml streptomycin, 2 mM l-glutamine, and 25 mM HEPES buffer). PMBC were counted and adjusted to 4×10^6 /ml for further analysis. Cells were then split for evaluation of proliferation and intracellular staining for flow cytometry, or for qRT-PCR, nitro-blue tetrazolium assay (NBT) (Sigma Aldrich, St. Louis, MO), or ELISPOT Assays.

Preparation of parasites - L. infantum (LIVT-2) grown for use as positive control for kqRT-PCR or freeze-thawed *L. infantum* antigen (f-t *L.i.*), prepared as previously described, frozen in liquid nitrogen with subsequent thaw at 37°C for 3 cycles, and stored at -80°C [4]. Leishmania infantum (LIVT-2) was grown in complete Grace's medium (incomplete Grace's supplemented with 20% fetal bovine serum, 100 U/ml penicillin, 100 µg/ml streptomycin, and 2 mM l-glutamine). Parasites were harvested, pelleted at 2500 x g for 15 min at 4°C, washed twice with phosphate-buffered salt solution (PBS), and suspended in PBS to a concentration of 10^7 parasites/ml. Ten 1:5 serial dilutions were made and 50 µL of each dilution was spiked into 150 µL of negative canine blood.

Antigen stimulation - Cells were stimulated with Concanavalin A (ConA; 5 µg/ml) for 4 days and f-t *L.i.* (10 µg/ml) for 7 days as previously described [4]. Asymptomatic dog PBMC

were stimulated with distemper virus vaccine (Pfizer, Kalamazoo, MI) as a Non-*Leishmania*, antigen Specific Control (NSC) for 10 days. 24 hours prior to cell harvest, 5-ethynyl-2'-deoxyuridine (EdU) (Invitrogen, Grand Island, NY) was added at 10 μ M, and 10 μ g/ml brefeldin A (Sigma, St. Louis, MO) was added 6 hours before harvest. Cells were harvested and washed prior to surface and intracellular labeling.

IL-10 and B7.H1 block - Non-adherent PBMC were removed and saved in separate culture. Adherent cell populations were CD3⁺ CD11b⁺ by flow cytometry (data not shown). Adherent cells were treated with 10 μ g/ml anti-B7.H1 antibody (eBioscience, San Diego, CA) or isotype for 4 hours, washed, and non-adherent cells were returned to culture for antigen-stimulation. This blocked adherent cell B7.H1 specifically. IL-10 block was performed via 10 μ g/ml anti-canine IL-10 antibody (R and D Systems, Minneapolis, MN).

PBMC immunolabeling – PBMC were labeled similarly to [4], with the following PBMC labeling panel: Canine PBMC labeling panel: EdU Click-It (Invitrogen, Grand Island, NY), anti-canine CD4/Alexafluor 647 (AbD Serotec, Raleigh, NC), anti-canine CD8/Alexafluor 700 (AbD Serotec, Raleigh, NC), anti-canine IFN γ /Zenon R-PE (R&D systems, Minneapolis, MN)(Invitrogen, Grand Island, NY), anti-canine IL-10/Zenon APC/Alexafluor 750 (R&D systems, Minneapolis, MN)(Invitrogen, Grand Island, NY), and anti-human biotinylated PD-1/PE-Cy7 streptavidin (R&D systems, Minneapolis, MN) (eBioscience, San Diego, CA). Cells blocked with 25 μ l of canine serum, with mouse and rat non-specific polyclonal IgG at 20 μ g/10⁶ PBMC for 20 minutes at 4°C. Cells were blocked for 20 minutes, 4°C, permeabilized with saponin reagent (Invitrogen, Grand Island, NY) and preserved in BD

stabilizing fixative (BD biosciences, San Jose, CA). Samples were analyzed within 48 hours. Data acquired via FACScanto (BD biosciences, San Jose, CA) with FlowJo analysis (TreeStar Inc., Ashland, OR).

ELISpot - PBMC were stimulated as previous and incubated on anti-canine IFN γ or IL-10 capture antibody coated plates (R&D systems, Minneapolis, MN). 100 μ l of 0.5 μ g/ml biotinylated detection antibody (R&D systems, Minneapolis, MN) was added. Spots counted as average of duplicate wells over 4 dilutions, standardized to spots per 10⁶ PBMC.

IL-10 ELISA - Supernatants from unlabeled PMBC (2×10^5) were collected at indicated time points and stored at -20°C until analysis. IL-10 production was measured via ELISA (R&D Systems, Minneapolis, MN) per manufacturer's recommendations.

Nitric oxide production – The concentration of nitrite was assessed by the Griess reaction, in which 50 μ l cell culture supernatant and Griess reagent (LabChem, Pittsburgh, PA) was mixed and incubated at RT. The absorbance was measured at 550nm via microplate reader (Molecular Devices, Sunnyvale, CA). Nitrite concentration determined via a sodium nitrite standard curve.

Superoxide production - Production of superoxide was assessed using Nitro Blue Tetrazolium (NBT) (Sigma Aldrich, St. Louis, MO) tablets. NBT tablets were dissolved in 1ml water, 30 μ l added to cells, and incubated for 60-90 minutes. Coverslips were harvested, fixed, and

stained with eosin. Cells were counted as percent cells containing formazan precipitate. All evaluations were based on average of 600 cells per experiment with blinding.

Polymerase chain reaction assay - DNA was isolated and RT-PCR performed as previously described (12). DNA was isolated using the Qiagen blood DNA isolation kit (Qiagen, Valencia, CA) according to the manufacturer's instructions. DNA quality and quantity were measured using a NanoDrop ND1000 spectrophotometer (Nanodrop, Wilmington, DE). *Leishmania* SSU rRNA specific fluorogenic probe (5'-6-carboxyfluorescein [6-FAM]-CGGTTCGGTGTGTGGCGCC-3') and its flanking primers (F, 5'-AAGTGCTTTCCCATCGCAACT-3'; R, 5'-CGCACTAAACCCCTCCAA-3' (Applied Biosystems, Foster City, CA) previously designed (Wortman et al. 2001) were used. Blood DNA samples were assayed via qPCR in duplicates of two dilutions (straight, 1:10) using a Stratagene Mx3005P qPCR system (Agilent, Santa Clara, CA) via a 96-well format and perfeCta qPCR SuperMix, Low ROX master mix (Quanta Biosciences, Gaithersburg, MD). Primers were used at 775 nM and probe at 150 nM, with thermocycling at 95°C for 3 min and 50 cycles of 95°C for 15 s, 60°C for 1 min. Results were analyzed via MxPro QPCR software version 4.01, Microsoft Excel, and GraphPad Prism version 5.04 (GraphPad Software, La Jolla, CA).

Statistical analysis – Statistical analysis was conducted with pair-wise Student's t-tests or one way ANOVA with a Tukey's post-test via Graph Pad Prism version 5.04 (GraphPad Software, La Jolla, CA), significance at $\alpha=0.05$. qRT-PCR data was log-transformed for one-way ANOVA analysis. Graphical data presented as arithmetic mean \pm SEM.

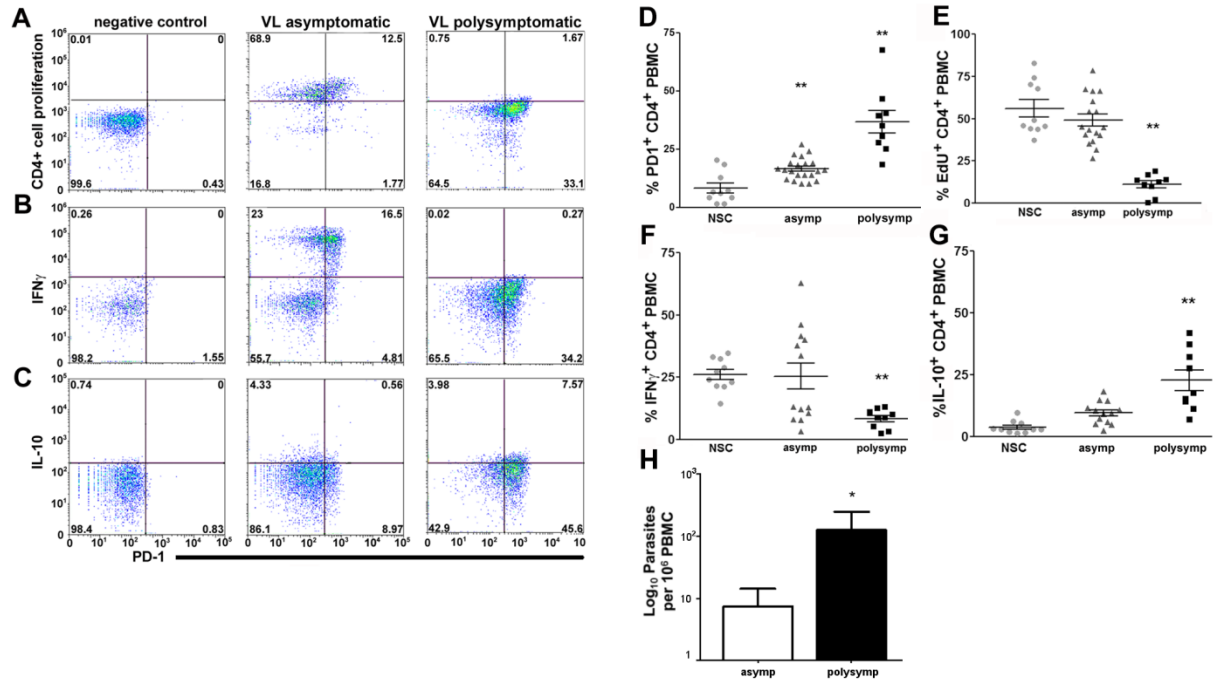


Figure 2.1. *Leishmania infantum* infection promotes progressive CD4⁺ T cell exhaustion. PBMC from *L. infantum*-infected dogs were stimulated with f-t *L. infantum*, or a non-mitogen antigen-specific positive control (NSC) (A-C) - CD4⁺ T cell plots of negative control (left), asymptomatic (middle), and symptomatic (right) dog PBMC for (A) CD4⁺ proliferation via EdU incorporation, (B) CD4⁺ IFN γ ⁺, and (C) CD4⁺ IL-10⁺, vs. PD-1⁺ in response to f-t *L. i.* (D-G) - Population graphs of CD4⁺ T cell (D) PD-1 surface expression, (E) proliferation measured via EdU incorporation, (F) IFN γ expression, and (G) IL-10 from NSC-stimulated, asymptomatic and symptomatic animals. (H) Peripheral blood parasite levels in asymptomatic and symptomatic dogs measured by qPCR, expressed as log number of parasites. All experiments included n > 21 dogs, 10 asymptomatic dogs for NSC. *p < 0.05, **p < 0.01 via one-way ANOVA with Tukey's post-test (A-G), or un-paired Student's-t-test (H).

RESULTS

CD4+ T cells from animals with visceral leishmaniasis displayed an exhausted phenotype.

Alteration in CD4⁺ effector function during VL is well established, with demonstrated involvement of IL-10, IL-4, TGFβ, and cells able to produce both IL-10 and IFNγ [2, 3]. We previously demonstrated these alterations in *L. infantum*-infected dogs as they progress to symptomatic VL [4]. These findings were suggestive of an exhausted phenotype. We obtained PBMC from dogs naturally infected with *L. infantum* and stimulated these cells with media, freeze-thawed *L. infantum* (f-t *L.i.*), Concanavalin A, or Canine Distemper antigen (Non-*Leishmania* Specific antigen Control) (NSC) to evaluate whether the phenotype of CD4⁺ and CD8⁺ T cells from dogs with asymptomatic and symptomatic VL infection was consistent with functional T cell exhaustion.

Population surface expression of PD-1 on CD4⁺ T cells was significantly increased in asymptomatic (two-fold) and symptomatic (four-fold) *L. infantum*-infected animals (Figure 2.1), as compared to expression on cells from asymptomatic dogs stimulated with a non-*Leishmania* antigen (NSC) *ex vivo* (Figure 2.1D). The percent of CD4⁺ T cells capable of proliferation in response to f-t *L.i.* antigen was significantly reduced in animals with symptomatic VL, with five-fold reduction compared to asymptomatic NSC and asymptomatic animals (Figure 2.1A, E). Intracellular staining revealed a 67% reduction in the percentage of CD4⁺ cells responding to f-t *L.i.* stimulation by IFNγ⁺ production compared to either NSC or asymptomatic animals (Figure 2.1B, F). Consistent with previous studies of leishmaniasis [2] and of T cell exhaustion [16, 17], the percentage of IL-10⁺ CD4⁺ T cells in f-t *L.i.*-stimulated PMBC from symptomatic animals increased almost six-fold and over two-fold compared to NSC and asymptomatic animals respectively (Figure 2.1C, G).

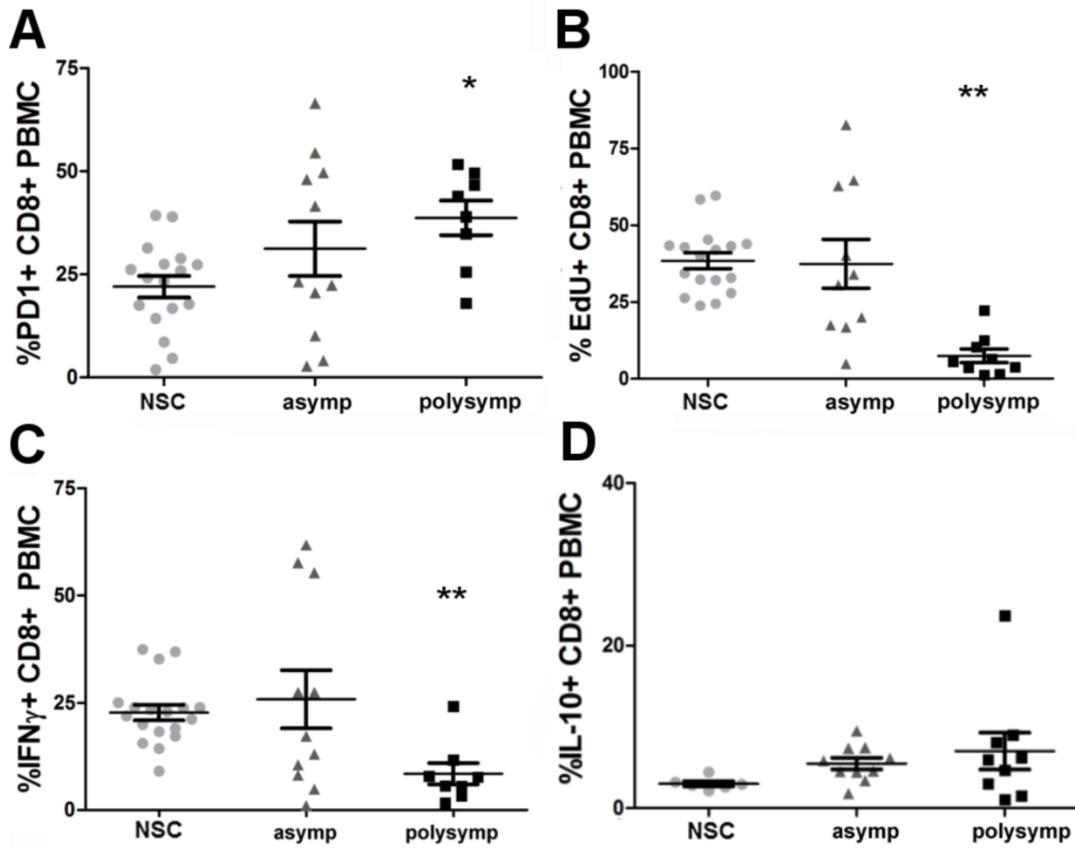


Figure 2.2. *Leishmania infantum* infection promotes progressive CD8⁺ T cell exhaustion. PBMC from *L. infantum*-infected dogs were stimulated with f-t *L. infantum*, or a non-mitogen antigen-specific positive control (NSC) (A-D) - Population graphs of CD8⁺ T cell (A) PD-1 surface expression, (B) proliferation measured via EdU incorporation, (C) IFN γ expression, and (D) IL-10 from NSC-stimulated, asymptomatic and symptomatic animals. All experiments included n>16 dogs, 17 dogs for NSC. *p<0.05 compared to NSC, **p<0.01 compared to all experimental groups via one-way ANOVA with Tukey's post-test (A-D).

We substantiated the alterations in IFN γ and IL-10 intracellular production via ELISpot after 16 hours in culture with media, f-t *L.i.*, or NSC (Supplemental Figure 2.1A, B). ELISpot and IL-10 ELISA demonstrated significant reductions in PBMC IFN γ production (Supplemental Figure 2.1A) and significant elevations in PBMC IL-10 production both in asymptomatic and symptomatic animals (Supplemental Figure 1B). Functional exhaustion and symptomatic VL was also associated with a significant increase in *L. infantum* burden within PBMC (Figure 2.1, H). The lack of antigen-specific CD4 $^{+}$ effector responses from these cells indicates the presence of CD4 $^{+}$ T cell exhaustion during VL, associated with increasing peripheral parasite load.

CD8 $^{+}$ T cells from asymptomatic and symptomatic VL animals displayed characteristics of exhaustion.

CD8 $^{+}$ T cell exhaustion has been previously characterized during numerous chronic viral infections, protozoal infections, and cutaneous leishmaniasis [6, 7, 9]. Pro-inflammatory cytokines, including IFN γ , are produced primarily by both CD4 $^{+}$ and CD8 $^{+}$ T cells during chronic VL [18]. The presentation of intracytoplasmic *L. infantum* antigen on MHC class I has been previously shown to be important for the immune response during leishmaniasis, although the mechanism is incompletely understood [19]. CD8 $^{+}$ T cell exhaustion has not been previously reported during naturally-occurring VL, and the relationship of CD4 $^{+}$ to CD8 $^{+}$ T cell exhaustion during VL progression is not known. We evaluated characteristics of exhaustion in CD8 $^{+}$ T cells from the peripheral blood of asymptomatic and symptomatic dogs infected with *Leishmania infantum*, after *ex vivo* stimulation with media, freeze-thawed *L. infantum* (f-t *L.i.*), concanavalin A (ConA), or canine distemper antigen (NSC).

Surface expression of PD-1 was significantly elevated in CD8⁺ T cells from animals with asymptomatic (1.5 fold increase) and symptomatic VL (two-fold increase) as compared to NSC (Figure 2.2A). Mean surface expression of PD-1 on CD8⁺ and CD4⁺ T cells from VL symptomatic animals was similar with means of 38.69 and 36.84 respectively (Figure 2.1D, 2.2A). However, during asymptomatic infection, the extent of CD8⁺ exhaustion was greater than in the CD4⁺ T cell population, with a higher number of dogs with significant impairment in CD8⁺ T cells during asymptomatic infection than in CD4⁺ T cells and elevated expression of PD-1 (Figure 2.2A, 1D). VL symptomatic animals had significant five-fold reduction in proliferative capacity (Figure 2.2B), and three-fold reduction in the capacity of CD8⁺ T cells to produce IFN γ (Figure 2.2C) in response to whole f-t *L.i.* compared either to NSC or asymptomatic animals. There was no significant change in intracellular IL-10 production. This data indicates the presence of pan-T cell exhaustion during symptomatic VL, and a large percentage (>40%) of asymptomatic animals with phenotypic CD8⁺ T cell exhaustion and elevated PD-1 (Figure 2.2A, B, C). T cell exhaustion during VL was associated with elevated expression of inhibitory receptor PD-1 and could potentially be identified prior to the onset of symptomatic disease. This exhaustion was associated with clinical progression of VL and could be a predominant contributing factor to the onset of symptomatic VL.

T cell exhaustion in CD4⁺ T cells from symptomatic VL animals is reversed by B7.H1 block.

An increased percentage of PD-1 expressing CD4⁺ T cells was progressively associated with CD4⁺ T exhaustion during symptomatic VL. Previous studies utilizing B7.H1 antibody block demonstrated recovery of CD8⁺ T cell effector function [16, 20]. Our

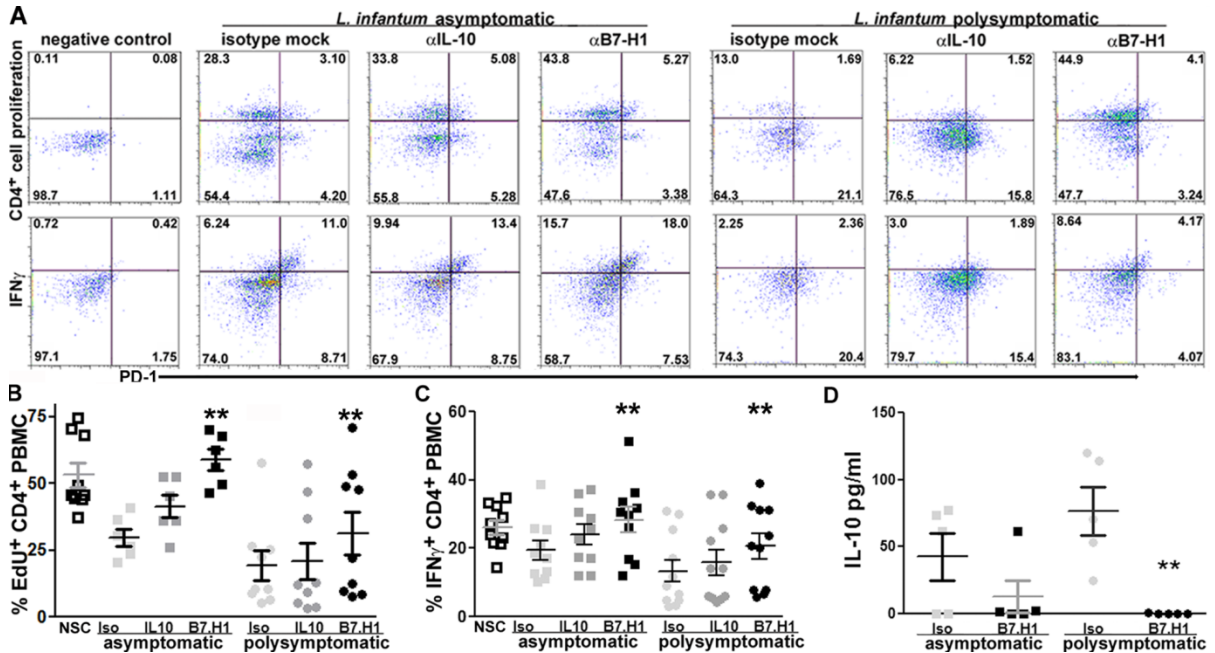


Figure 2.3. PD-1/B7.H1 interaction necessary for CD4⁺ T cell exhaustion during symptomatic VL. Adherent PBMC treated with B7.H1 blocking antibody or IL-10 blocking antibody. PBMC stimulated as previous. **(A)** CD4⁺ cellular proliferation (top row) and CD4⁺ T cell IFN γ (bottom row), compared to PD-1 (x-axis) in PBMC from negative control (left), asymptomatic VL (middle), and symptomatic VL (right) dogs, with isotype control (left), anti-IL-10 antibody (center), or anti-B7.H1 antibody treatment (right). **(B)** CD4⁺ cellular proliferation, n=15. **(C)** CD4⁺ PBMC IFN γ intracellular production, n=21. **(D)** Production of IL-10 via ELISA, n=11. **p<0.01, via one way ANOVA with Tukey's post-test.

previous studies demonstrated an increased percentage of IL-10-producing CD4⁺ T cells and increased IL-10 production during symptomatic VL. Others have postulated that IL-10 may induce CD4⁺ T cell suppression during chronic VL [2, 21]. Based on this, our hypothesis was that IL-10/IL-10R and/or PD-1/PDL-1 (B7.H1) signaling is necessary for CD4⁺ T cell exhaustion in PBMC from symptomatic VL animals. Block of B7.H1 resulted in significant recovery in the population of CD4⁺ T cells able to proliferate to f-t *L.i.* both in asymptomatic and symptomatic infection-derived PBMC (Figure 2.3 A, B). A lesser magnitude of recovery was associated with greater severity of clinical disease and more extensive T cell exhaustion (Figure 2.3 and data not shown). The IL-10 block trended toward increased proliferation-capable CD4⁺ T cells in PBMC from both asymptomatic and symptomatic animals and was not statistically significant (Figure 2.3). B7.H1 block resulted in significant recovery of a population of CD4⁺ IFN γ ⁺ T cells compared to isotype or IL-10 antibody-treated PBMC from symptomatic animals and compared to isotype-treated PBMC from asymptomatic animals (Figure 2.3A, C). The number of IFN γ -producing PBMC was also significantly increased after B7.H1 blockage compared to isotype or to IL-10 treatment as measured via ELISpot (Supplemental Figure 2A). Recovery of a population of IFN γ producing cells after anti-IL-10 antibody treatment trended towards significance but was not significantly altered compared to isotype treated-PBMC (Figure 2.3A, C). IL-10 production as measured by ELISA was significantly reduced after B7.H1 block as compared to IL-10 production from PBMC treated with isotype antibody (Figure 2.3D). The population of IL-10⁺ PBMC quantified via ELISpot increased after blockage of B7.H1 and stimulation with f-t. *L.i.*, perhaps suggesting transformation of IL-10 expressing cells into IFN- γ coexpression, similar to previous findings [2] (Supplemental Figure 2B).

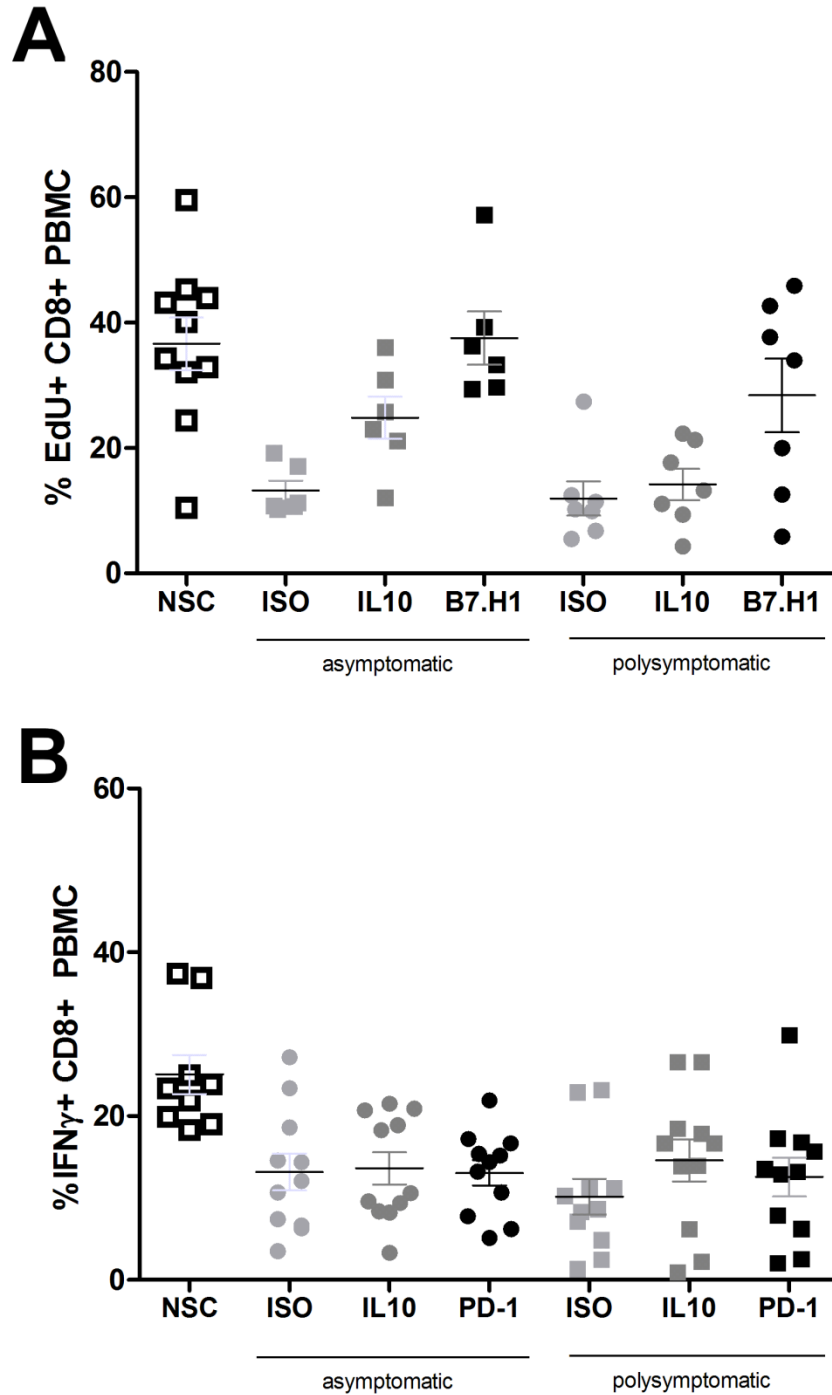


Figure 2.4. PD-1/B7.H1 interaction necessary for suppression of proliferation but not IFN γ production during symptomatic VL-associated CD8+ T cell exhaustion. Adherent PBMC treated with B7.H1 blocking antibody or IL-10 blocking antibody. PBMC stimulated as previous. **(A)** CD8+ cellular proliferation, n=13. **(B)** CD8+ PBMC IFN γ intracellular production, n=22. **p<0.01, via one way ANOVA with Tukey's post-test.

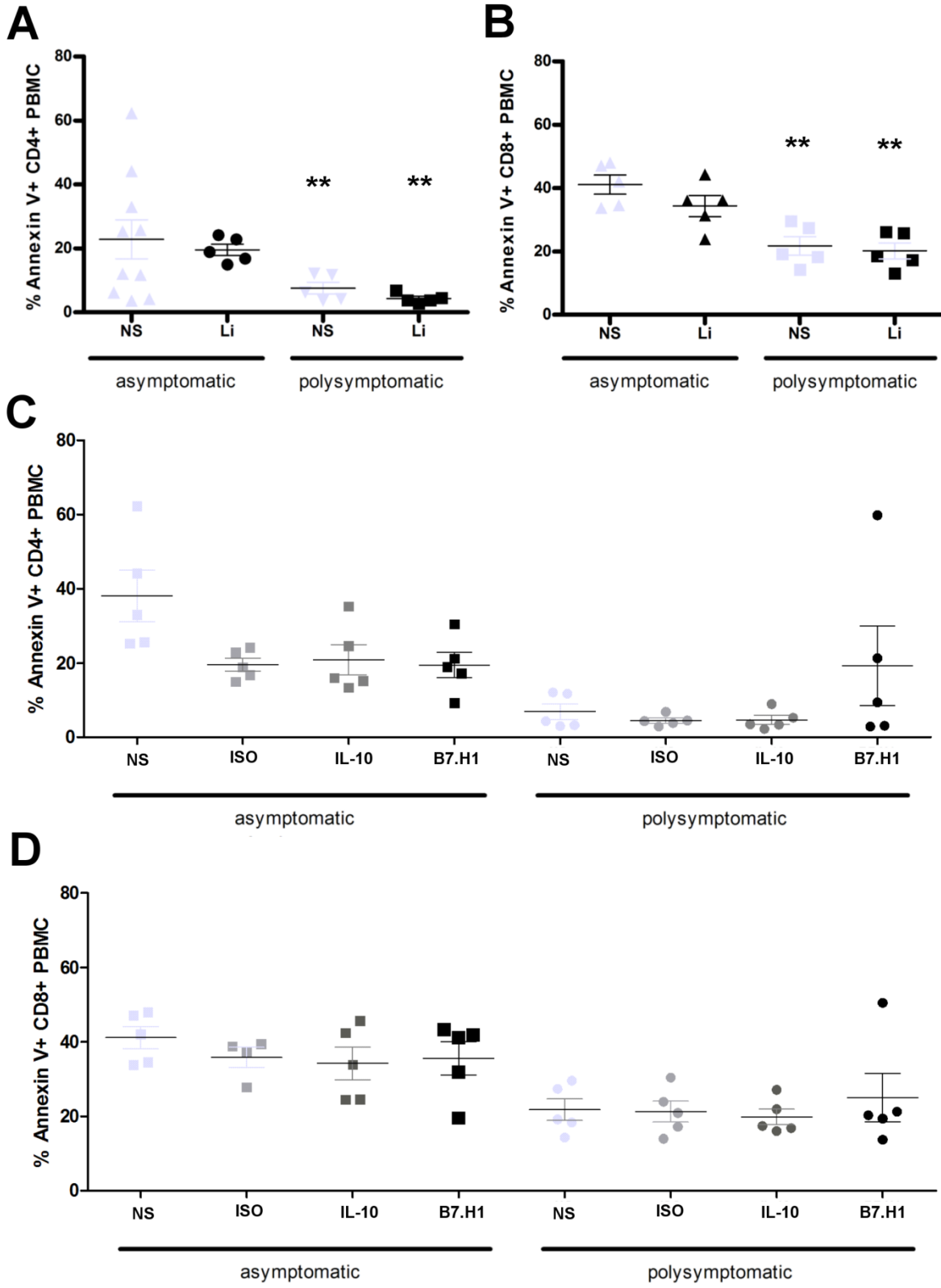
Blockage of the PD-1/B7.H1 interaction has been tested as a means for recovery of CD8+ T cell responses during chronic infections and has completed stage 1 clinical safety and efficacy trials for cancer immunotherapy [22, 23]. Mechanisms and effects of PD-1/B7.H1 on CD4+ cells are poorly understood [8]. Blockage of B7.H1 was consistently effective in increasing the antigen-responsive population of CD4+ T cells from both asymptomatic and symptomatic VL animals, significantly increasing the percentage of cells able to proliferate and produce IFN- γ after B7.H1 treatment. PD-1 is therefore necessary for CD4+ T cell exhaustion during VL, and blocking the PD-1/B7.H1 interaction recovered a population of functional Th1 CD4+ T cells.

Blockage of B7.H1/PD-1 recovers proliferation in exhausted CD8+ T cells but not IFN γ production.

Exhaustion of CD8+ T cells from peripheral blood in both asymptomatic and symptomatic animals was associated with a significant elevation of PD-1 surface expression (Figure 2.2). Blockage of the B7.H1/PD-1 interaction but not IL-10 significantly recovered both proliferation and IFN γ production within the CD4+ T cell population in response to stimulation with f-t *L.i.* (Figure 2.3). To evaluate the role of PD-1 and IL-10 in suppressing CD8+ T cell function, we blocked B7.H1 and IL-10 prior to stimulation with f-t *L.i.* and evaluated CD8+ T cells after 7 days in culture (Figure 2.4).

Consistent with B7.H1 blockage in the CD4+ T cell population, B7.H1/PD-1 blockage on adherent PBMC significantly increased proliferative capacity in response to f-t *L.i.* in both asymptomatic and symptomatic animals (Figure 2.4A). As opposed to the CD4+ T cell population, blockage of IL-10 also significantly recovered CD8+ T cell function

Figure 2.5. *L. infantum* exhausted T cells do not undergo apoptosis or cell death in response to antigen stimulation. (A, B) Annexin V and PI (not shown) positivity was measured in asymptomatic or poly-symptomatic VL dogs after no stimulation and stimulation with 10 µg/ml f-t *L.i.* for 7 days. PBMC were gated on CD4+ (A) or CD8+ (B) live lymphocytes based on isotype control. (C, D) Annexin V positivity was measured similarly to 3A, after blocking with isotype, IL-10, or B7.H1 blocking antibodies in CD4+ (C) and CD8+ (D). **p<0.01 via one way ANOVA with tukey post-test in GraphPad Prism 5. Experiments included n=10 client-owned patients.



after f-t *L.i.* stimulation in asymptomatic animals (Figure 2.4A). However, within the CD8+ T cell population, blockage of PD-1 did not significantly recover IFN γ production in either asymptomatic or symptomatic dogs (Figure 2.4B). In symptomatic dogs, blockage of IL-10 significantly recovered IFN γ production, although recovery was minimal compared to positive control (Figure 2.4B). This indicates in these asymptomatic and symptomatic dogs, the CD8+ T cell population recovery of IFN γ production is largely non-responsive to blockage of PD-1/B7.H1.

Antigen stimulation does not induce apoptosis in exhausted T cells

Previous research has demonstrated the step-wise manner in which CD4+ and CD8+ T cell populations progress through exhaustion [8, 9]. Shin et al. demonstrated the persistence of exhausted T cells *in vivo*, maintained through basal levels of proliferation and antigen stimulation independent of IL-7 and IL-15 [10]. To evaluate apoptosis of T cells during symptomatic VL, we evaluated PBMC at 7 days after f-t *L.i.* stimulation for Annexin V and propidium iodide positivity (Figure 2.5). Propidium iodide positivity indicative of cell death was low in all groups evaluated (data not shown). Annexin V positivity was higher within the CD8+ T cell population than within the CD4+ T cell population from both symptomatic and asymptomatic animals across all experimental treatments (Figure 2.5A-D). However, Annexin V positivity was higher in CD4+ and CD8+ T cells from asymptomatic animals than in T cells from symptomatic animals. After blockage of IL-10 or the PD-1/B7.H1 interaction, CD4+ and CD8+ T cell apoptosis measured through Annexin V was still significantly lower within the symptomatic group than the asymptomatic group (Figure

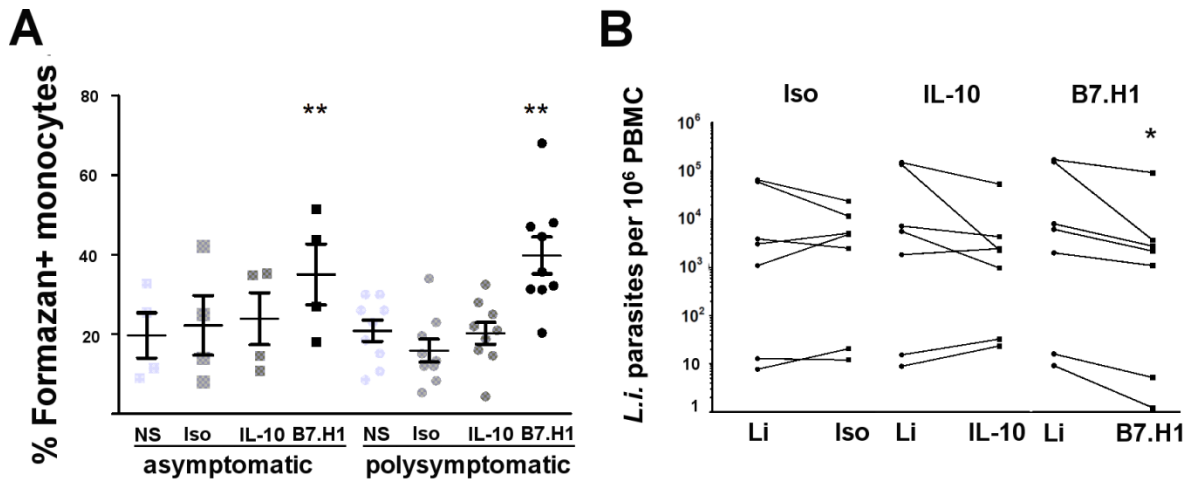


Figure 2.6. B7.H1 block increased phagocyte superoxide production and decreased parasite load. (A) NBT assay performed on adherent PBMC from asymptomatic and symptomatic VL dogs after isotype, B7.H1, or IL-10 antibody treatment and stimulation with f-t *L.i.*. (B) *L. infantum*-specific quantitative RT-PCR performed on PBMC DNA. Data presented as number of genomic copies of *L. infantum*/10⁶ PBMC from symptomatic dogs, after f-t *L.i.* stimulation (Li) compared to stimulation and addition of isotype, (left, Iso), anti-IL-10 (middle, IL-10), or anti-B7.H1 antibody (right, B7.H1). (A) n=13 and (B) n=7. *p<0.05, **p<0.01, via one way ANOVA with Tukey's post-test on averaged (A) or log-transformed (B) data.

2.5C, D). There were no significant differences in Annexin V positivity between experimental treatments (Figure 2.5C, D). Blocking of B7.H1 in CD4+ T cells from symptomatic VL animals resulted in a slight trend toward increased Annexin V positivity, corresponding to the degree of recovered proliferation, with 3 animals that had increasing PBMC proliferation and also Annexin positivity, and 2 animals (also the lowest proliferators and producers of IFN γ from Figure 2.3B, C) without alteration in PBMC Annexin V positivity, proliferation, or IFN γ production. Within the CD8+ T cell population, there was no change in Annexin V positive cells in any experimental group (Figure 2.5D). This data suggests that in the presence of antigen, exhausted CD4+ T cells are unable to proliferate, but

are not induced to undergo apoptosis after continued antigen stimulation. This is consistent with previous reports in CD8⁺ exhaustion during LCMV infection of mice, where exhausted populations of CD8⁺ T cells were maintained in the continued presence of antigen [10]. However, within the CD8⁺ T cell population, recovery of proliferation did not correspond with an increase in Annexin positivity, indicating that this population does not respond to antigen by undergoing apoptosis after seven days in culture, even after recovery of proliferative potential.

B7.H1 blockage improves the production of superoxide and parasite clearance in phagocytic monocytes.

Previous reports demonstrated the importance of ROI and RNI in reducing intracellular *Leishmania* burden [1, 14]. Phagocyte production of ROI and RNI required IFN γ production by T cells [15]. We demonstrated that blocking PD-1/B7.H1 signaling recovered a population of CD4⁺ T cells with IFN- γ production. We sought to determine how functional Th1 cell recovery altered phagocyte function, as phagocytes are both the target of *L. infantum* infection and necessary for *L. infantum* removal. After PD-1/B7.H1 block, *L.i.* antigen-stimulated monocyte-derived phagocytes from asymptomatic and symptomatic dogs produced significantly more superoxide compared to all other treatments (Figure 6A, Supplemental Figure 2D). Nitric oxide production, as measured by Griess reaction performed on cell supernatants from identical PBMC cultures, had no significant differences between any experimental groups (Supplemental Figure 2C). Dogs, like humans, have limited iNOS activity. There is continuing debate as to the importance of RNI in the killing of intracellular pathogens in species other than mice, including humans and dogs [15, 24].

Blocking PD-1/B7.H1 increased superoxide production in adherent monocytes from symptomatic dogs chronically infected with *L. infantum* (Figure 2.6A). Regaining an ability in these cells to produce parasite-lethal reactive oxygen species provides a link between restoration of CD4+ T helper function and improved monocyte-derived phagocyte function. We next wanted to identify whether this increase in ROI-producing phagocytes led to reduced intra-PBMC parasites *ex vivo* from VL asymptomatic and symptomatic dogs. We quantified PBMC parasite load after PD-1/B7.H1 treatment via RT-PCR. After B7.H1 block, parasite-stimulated PBMC from symptomatic animals had significantly fewer *L. infantum* parasites than f-t *L.i.*-stimulated PBMC or isotype-antibody treated PBMC using paired PBMC from the same dogs (Figure 2.6B). The average reduction in *L. infantum* after B7.H1 blockage was 0.58 log or 67.36%. While not significant, IL-10 block reduced parasite load in the four dogs with highest parasitemia (p=0.16) (Figure 2.6B, IL-10). Reduction of *L. infantum* in PBMC after blockage of B7.H1/PD-1 strongly suggests that PD1-PD1L signaling within the phagocyte has a significant suppressive role on the ability of phagocytes to induce an oxidative burst, permissive to *L. infantum* survival.

DISCUSSION

Effective vaccination and immunotherapeutic strategies for VL have remained elusive [25]. Host and parasite factors regulating the balance of an asymptomatic state versus symptomatic clinical disease are incompletely understood for VL and are integral for addressing VL immunity [1]. Mice do not acquire symptomatic VL, therefore are largely inadequate for characterizing this host-pathogen interaction. In contrast, the canine model has similar pathogenesis to human VL and is valued as a target for public health interventions

including vaccination and therapy, in areas where dogs are the domestic reservoir of VL [4, 26].

Using naturally-occurring canine VL, we identified decreased PBMC production of IFN γ , decreased CD4⁺ T cell proliferation to antigen stimulation, and increased IL-10 production during clinical disease [4]; an exhausted phenotype. CD8⁺ T cell exhaustion has been identified in numerous infections, including disseminated cutaneous leishmaniasis [7-9, 27]. CD8⁺ exhaustion is characterized by absence of antigen-specific responses including proliferation, CD8⁺ cytotoxicity, and IFN γ production [28]. Knowledge of CD4⁺ T cell exhaustion is less extensive [8]. Here we demonstrate for the first time concurrent CD4⁺ and CD8⁺ T cell exhaustion during naturally occurring symptomatic VL in a canine model, mediated by PD-1/B7.H1. These CD4⁺ T cells were phenotypically exhausted, with impaired proliferation and IFN γ production in response to *L. infantum* antigen. We demonstrate CD8⁺ T cell exhaustion, partially mediated by PD-1, which occurs prior to the onset of symptomatic disease, and prior to the onset of functional CD4⁺ T cell exhaustion. It is logical, from an evolutionary standpoint that CD8⁺ T cells are more sensitive than CD4⁺ to tolerogenic stimuli, including prolonged antigen stimulation during chronic infection. This would protect infected cells from being the target of cytotoxic responses, and may significantly dampen pro-inflammatory stimuli with potential to induce host pathology [29]. Based on this clinical data, it is possible that concurrent CD4⁺ and CD8⁺ T cell exhaustion preceding the onset of clinical disease, contribute to the onset of symptomatic VL and non-response to therapy.

CD4⁺ T cells from symptomatic animals also had a significant reduction in Annexin V positivity, with minimal apoptosis. CD8⁺ populations also had reduced Annexin V

positivity compared to control, although the CD8⁺ T cell population seemed to undergo a greater degree of apoptosis in culture than CD4⁺ T cells. Reductions in apoptosis could be due to the clonal deletion of antigen specific T cells or to the non-response of these cells. Within both CD4⁺ and CD8⁺ T cell populations, blockage of B7.H1 significantly increased proliferative capacity and in the CD4⁺ population IFN γ . This makes clonal deletion unlikely, as an antigen-specific population could be recovered. A more likely explanation is the antigen-addiction theory put forth by Wherry, supported by previously conducted research [8, 10]. This would suggest that the CD8⁺ and CD4⁺ T cell populations contain antigen-experienced cells that do not respond to antigen by undergoing proliferation, but also do not undergo apoptosis after antigen stimulation. Possible mechanisms for this would include antigen-driven survival, perhaps through cytokines such as IL-2 and T cell receptor engagement, or less likely through replicative senescence, which occurs due to epigenetic modification and telomere shortening during aging and prolonged cellular replication [30-32].

We also identified increased APC superoxide production and reduced intracellular parasites *ex vivo* after PD-1/B7.H1 block, indicating a role for this signaling pathway in altering phagocyte function as VL progresses. The importance of production of ROI and RNI are well documented components of effective immunity against *Leishmania* species and other intracellular pathogens [1]. Due to the dramatic alterations in both phagocyte, CD4⁺ T cell, and CD8⁺ T cell effector function after *ex vivo* PD-1/B7.H1 block, this therapy may be a means of inducing increased pro-inflammatory phagocyte function, and therefore a strong target for VL immunotherapy.

A recent report demonstrates the importance of CD4+ T cell exhaustion in the development of CD8+ T cell exhaustion [33]. In the presence of chronic infection it is likely that these two processes are extensively intertwined. Previous studies aimed at VL immunotherapy have targeted IFN γ , blocking IL-10, or using TLR agonists [21, 34]. Limited success of these immunotherapeutic approaches suggests that there are other, perhaps more significant, mechanisms of immune dysregulation during VL. This study demonstrates concurrent CD4+ and CD8+ T cell exhaustion, often present prior to the onset of symptomatic VL, mediated in part by significantly elevated surface expression of coinhibitory molecule PD-1. T cell exhaustion may be a major contributor to the onset of symptomatic VL, and demonstrates potential as a target for immunotherapy.

ACKNOWLEDGEMENTS

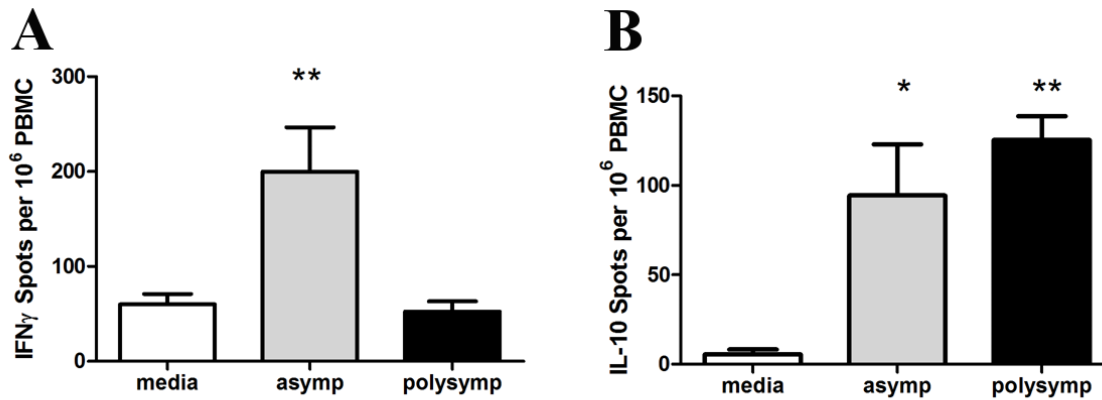
We thank Mary E. Wilson and Selma M.B. Jeronimo, for their critical review regarding this manuscript. We thank our collaborating Foxhound hunts for assistance with their priceless dogs.

FOOTNOTES

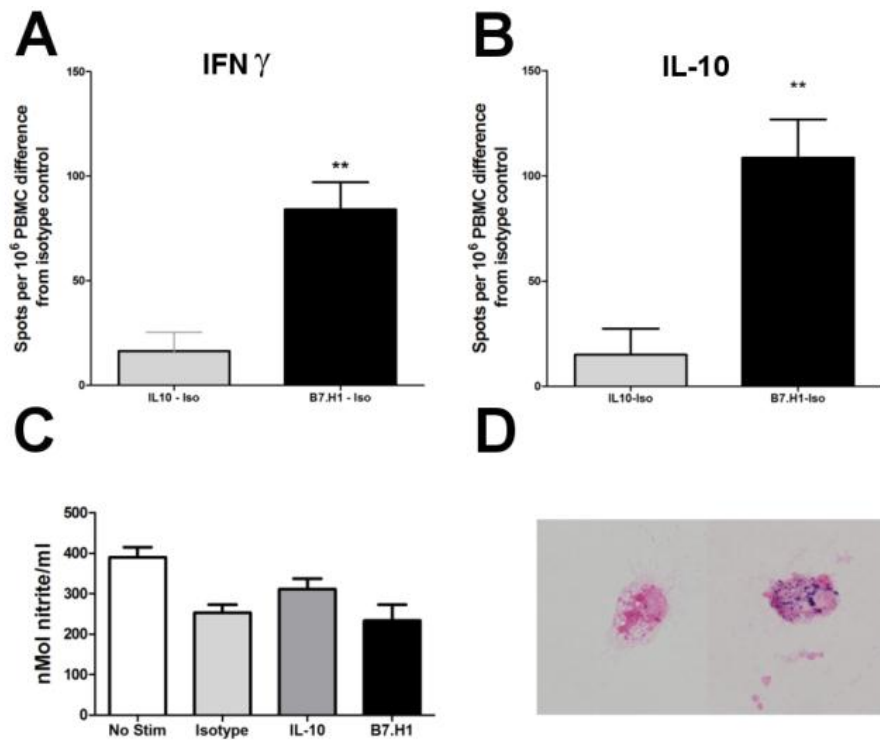
¹ Funding: work supported by National Institutes of Health grant AI50803 and Pfizer Animal Health/Morris Animal Foundation Fellowship for Advanced Study.

* Corresponding author and reprint requests: Mailing address: Room 2714, Department of Veterinary Pathology, Iowa State University, 1600 University Boulevard, Ames, IA 50011.

E-mail address: kalicat@iastate.edu.



Supplemental Figure 1. Poly-symptomatic VL causes a reduction in the number of IFN γ producing PBMC, an increase in IL-10 producing PBMC, and enhanced survival in the presence of *f-t L.i.* antigen ex vivo. **(A, B)** ELISPOTS for IFN γ and IL-10 were performed with PBMC harvested from asymptomatic and poly-symptomatic VL dogs. Counts are the average of 4, 2-fold dilutions in duplicate per animal. PBMC were gated on live lymphocytes, and then CD4 positivity based on fluorescence minus one isotype controls. * $p < 0.05$, ** $p < 0.01$, via one way ANOVA with Tukey's post-test. Experiments included $n=14$ **(A, B)**.



Supplemental Figure 2. Blockage of B7.H1 recovers the number of IFN γ producing PBMC and increases the number of IL-10 producing and apoptotic PBMC ex vivo, with subsequent effects on superoxide production in monocyte-derived phagocytes. **(A, B)** ELISPOTS for IFN γ and IL-10 were performed with PBMC harvested from poly-symptomatic VL dogs after B7.H1 and IL-10 blockage and stimulation with 10 mg/ml f-t *L.i.* Counts are the average of 4, 2-fold dilutions in duplicate per animal with subtraction of isotype blocking controls. **(C)** Greiss assay for nitrite production was performed on PBMC cell culture supernatants after 18 hours of stimulation with 10 mg/ml f-t *L.i.* and blocking with isotype, IL-10, or B7.H1 blocking as described in the *materials and methods*. **(D)** Representative image of monocyte-derived phagocytes from isotype blocking (left) or B7.H1 blocking (right), the results of which are presented in Figure 3A. * $p < 0.05$, ** $p < 0.01$, via one way ANOVA with Tukey's post-test.

REFERENCES

1. **Kaye, P. and P. Scott**, *Leishmaniasis: complexity at the host-pathogen interface*. Nat Rev Microbiol, 2011. **9**(8): p. 604-15.
2. **Nylen, S., et al.**, *Splenic accumulation of IL-10 mRNA in T cells distinct from CD4+CD25+ (Foxp3) regulatory T cells in human visceral leishmaniasis*. J Exp Med, 2007. **204**(4): p. 805-17.
3. **Wilson, M.E., et al.**, *The TGF-beta response to Leishmania chagasi in the absence of IL-12*. Eur J Immunol, 2002. **32**(12): p. 3556-65.
4. **Boggiatto, P.M., et al.**, *Immunologic indicators of clinical progression during canine Leishmania infantum infection*. Clin Vaccine Immunol, 2010. **17**(2): p. 267-73.
5. **Zajac, A.J., et al.**, *Viral immune evasion due to persistence of activated T cells without effector function*. J Exp Med, 1998. **188**(12): p. 2205-13.
6. **Bhadra, R., et al.**, *Control of Toxoplasma reactivation by rescue of dysfunctional CD8+ T-cell response via PD-1-PDL-1 blockade*. Proc Natl Acad Sci U S A, 2011. **108**(22): p. 9196-201.
7. **Hernandez-Ruiz, J., et al.**, *CD8 cells of patients with diffuse cutaneous leishmaniasis display functional exhaustion: the latter is reversed, in vitro, by TLR2 agonists*. PLoS Negl Trop Dis, 2010. **4**(11): p. e871.
8. **Wherry, E.J.**, *T cell exhaustion*. Nat Immunol, 2011. **12**(6): p. 492-9.
9. **Wherry, E.J., et al.**, *Viral persistence alters CD8 T-cell immunodominance and tissue distribution and results in distinct stages of functional impairment*. J Virol, 2003. **77**(8): p. 4911-27.
10. **Shin, H., et al.**, *Viral antigen and extensive division maintain virus-specific CD8 T cells during chronic infection*. J Exp Med, 2007. **204**(4): p. 941-9.
11. **Gray, P.M., et al.**, *Antigen-experienced T cells limit the priming of naive T cells during infection with Leishmania major*. J Immunol, 2006. **177**(2): p. 925-33.
12. **Barron, L., et al.**, *Cutting edge: contributions of apoptosis and anergy to systemic T cell tolerance*. J Immunol, 2008. **180**(5): p. 2762-6.
13. **Gantt, K.R., et al.**, *Oxidative responses of human and murine macrophages during phagocytosis of Leishmania chagasi*. J Immunol, 2001. **167**(2): p. 893-901.

14. **Murray, H.W. and C.F. Nathan**, *Macrophage microbicidal mechanisms in vivo: reactive nitrogen versus oxygen intermediates in the killing of intracellular visceral Leishmania donovani*. J Exp Med, 1999. **189**(4): p. 741-6.
15. **Nathan, C.**, *Role of iNOS in human host defense*. Science, 2006. **312**(5782): p. 1874-5; author reply 1874-5.
16. **Barber, D.L., et al.**, *Restoring function in exhausted CD8 T cells during chronic viral infection*. Nature, 2006. **439**(7077): p. 682-7.
17. **Wherry, E.J. and R. Ahmed**, *Memory CD8 T-cell differentiation during viral infection*. J Virol, 2004. **78**(11): p. 5535-45.
18. **Kaye, P.M. and T. Aebischer**, *Visceral leishmaniasis: immunology and prospects for a vaccine*. Clin Microbiol Infect, 2011. **17**(10): p. 1462-70.
19. **Ruiz, J.H. and I. Becker**, *CD8 cytotoxic T cells in cutaneous leishmaniasis*. Parasite Immunol, 2007. **29**(12): p. 671-8.
20. **Joshi, T., et al.**, *B7-H1 blockade increases survival of dysfunctional CD8(+) T cells and confers protection against Leishmania donovani infections*. PLoS Pathog, 2009. **5**(5): p. e1000431.
21. **Gautam, S., et al.**, *IL-10 neutralization promotes parasite clearance in splenic aspirate cells from patients with visceral leishmaniasis*. J Infect Dis, 2011. **204**(7): p. 1134-7.
22. **Currie, A.J., et al.**, *Dual control of antitumor CD8 T cells through the programmed death-1/programmed death-ligand 1 pathway and immunosuppressive CD4 T cells: regulation and counterregulation*. J Immunol, 2009. **183**(12): p. 7898-908.
23. **Brahmer, J.R., et al.**, *Safety and activity of anti-PD-L1 antibody in patients with advanced cancer*. N Engl J Med, 2012. **366**(26): p. 2455-65.
24. **Panaro, M.A., et al.**, *Canine leishmaniasis in Southern Italy: a role for nitric oxide released from activated macrophages in asymptomatic infection?* Parasit Vectors, 2008. **1**(1): p. 10.
25. **Chappuis, F., et al.**, *Visceral leishmaniasis: what are the needs for diagnosis, treatment and control?* Nat Rev Microbiol, 2007. **5**(11): p. 873-82.

26. **Esch, K.J., et al.**, *Preventing zoonotic canine leishmaniasis in northeastern Brazil: pet attachment and adoption of community leishmania prevention.* Am J Trop Med Hyg, 2012. **87**(5): p. 822-31.
27. **Said, E.A., et al.**, *Programmed death-1-induced interleukin-10 production by monocytes impairs CD4+ T cell activation during HIV infection.* Nat Med, 2010. **16**(4): p. 452-9.
28. **Mueller, S.N. and R. Ahmed**, *High antigen levels are the cause of T cell exhaustion during chronic viral infection.* Proc Natl Acad Sci U S A, 2009. **106**(21): p. 8623-8.
29. **Reynoso, E.D., et al.**, *Intestinal tolerance is converted to autoimmune enteritis upon PD-1 ligand blockade.* J Immunol, 2009. **182**(4): p. 2102-12.
30. **Akbar, A.N. and S.M. Henson**, *Are senescence and exhaustion intertwined or unrelated processes that compromise immunity?* Nat Rev Immunol, 2011. **11**(4): p. 289-95.
31. **van Baarle, D., et al.**, *Progressive telomere shortening of Epstein-Barr virus-specific memory T cells during HIV infection: contributor to exhaustion?* J Infect Dis, 2008. **198**(9): p. 1353-7.
32. **Fletcher, J.M., et al.**, *Cytomegalovirus-specific CD4+ T cells in healthy carriers are continuously driven to replicative exhaustion.* J Immunol, 2005. **175**(12): p. 8218-25.
33. **Aubert, R.D., et al.**, *Antigen-specific CD4 T-cell help rescues exhausted CD8 T cells during chronic viral infection.* Proc Natl Acad Sci U S A, 2011. **108**(52): p. 21182-7.
34. **Raman, V.S., et al.**, *Applying TLR synergy in immunotherapy: implications in cutaneous leishmaniasis.* J Immunol, 2010. **185**(3): p. 1701-10.

CHAPTER 3

**ACTIVATION OF AUTOPHAGY AND THE NALP3 INFLAMMASOME
DURING *LEISHMANIA INFANTUM*-ASSOCIATED
GLOMERULONEPHRITIS**

K.J. Esch¹, E.M. Whitley¹, S.M.B. Jeronimo², J.S. Haynes¹, and C.A. Petersen¹

A manuscript to be submitted to the American Journal of Pathology

¹Department of Veterinary Pathology, College of Veterinary Medicine, Iowa State University,

²Department of Biochemistry, Federal University of Rio Grande do Norte, Natal, Brazil

ABSTRACT

Chronic kidney disease is a major health burden globally, and a major contributor to both human and companion animal morbidity and mortality. Renal complications are common as a sequelae to canine (>96% of cases) and human visceral leishmaniasis (VL) (25-30% of cases). Despite the high incidence of infection-mediated glomerulonephritis, little is known about the pathogenesis and mechanisms of VL-associated renal disease. Due to similarities in the immune response, immunopathology, clinical signs, and pathophysiology, *L. infantum*-infected dogs serve as a naturally-occurring model of VL and VL-associated glomerulonephritis. The study objectives were to identify glomerular alterations associated with glomerular injury and evaluate glomerular cellular responses during canine VL-associated glomerulonephritis. We evaluated a cohort of dogs infected with *L. infantum* from

the United States (n=15), *L. infantum*-infected dogs from an endemic area of Northeastern Brazil (n=10), and *Leishmania*-negative controls (n=5). Analysis of glomeruli demonstrated the presence of *Leishmania* antigen, IgG, and complement protein C3b. Evaluation of glomerular Nod-Like Receptor Protein 3 (NLRP3) and Microtubule-Associated Protein 1 Light Chain 3 (LC3) suggest alterations in inflammasome and autophagosome activity associated with lesion severity and clinical disease status. Membranoproliferative glomerulonephritis type I (24/25, 96%), with interstitial lymphoplasmacytic nephritis (23/25, 92%), and glomerular and interstitial fibrosis (12/25, 48%) were the predominant lesions. Ultrastructural evaluation of glomeruli from animals with clinical VL identified mesangial cell proliferation, mesangial cell interposition, and sub-endothelial and mesangial segmental electron-dense protein deposits. VL glomerulonephritis was mediated by antibody complex and complement deposition within the glomerulus, leading to NLRP3 inflammasome positivity, concomitant with LC3 autophagosome increased presence in dogs with clinical VL and renal failure. These findings elucidate potential novel mechanisms of glomerular responses to pathologic insult.

INTRODUCTION

Kidney disease is a major contributor to morbidity and mortality in canine and human populations. In the United States, there are an estimated 4.4 million non-institutionalized adults with renal disease, and renal disease ranks ninth as a cause of death in the United States [1, 2]. Health care costs associated with end-stage renal disease (ESRD) resulting in the necessity for long-term dialysis were approximately \$33 billion USD in 2010 [3, 4]. Immune-mediated glomerular disease accounts for a large percentage of ESRD cases, with a wide spectrum of causes, lesions and sequelae [1]. The traditional WHO classification

scheme for immune-mediated glomerulopathy is based upon histopathologic and ultrastructural characteristics, categorizing cases as membranous or membranoproliferative [5]. Membranoproliferative glomerulonephritis is traditionally further classified as Type I, II, or III based on the location and character of protein deposits [5]. These characterizations are however, based on morphology rather than specific cause, and can often be found a spectrum of changes within a single biopsy, or can differ by the clinical stage by a single causative agent.

Recent efforts to reclassify membranoproliferative glomerulonephritis (MPGN) by pathogenesis are thought to be more predictive of clinical outcome and may help target therapy. The new classification scheme uses immunofluorescence or immunohistochemistry to define lesions as immune-complex MPGN (with IgG, IgM, and/or complement), as immunoglobulin negative C3 glomerulopathy, or dense deposit disease [5, 6]. The podocyte, a versatile, long-lived cell type constructing the glomerular filtration slit, and the mesangial cell, which is a major resident phagocyte within the glomerular mesangium, play definitive roles in MPGN. As previously mentioned, the reaction of mesangial cells and ultrastructural changes and eventual apoptosis of glomerular podocytes are the basis for traditional classification of MPGN. Even with a greater understanding of the root causes of MPGN and their association with therapeutic efficacy and prognosis, relatively little is known of how the glomerular apparatus (podocytes, mesangial cells, endothelial cells) responds to injurious inflammatory stimuli. Multiple reports have demonstrated the importance of autophagy in the maintenance of the GBM as a normal function of podocytes [7-10]. Podocyte specific knockout of LC3, a major autophagy protein, results in a phenotype of glomerulosclerosis due to the accumulation of poly-ubiquitinated proteins by 24 months [7]. In addition

elevations in LC3 have been previously identified in response to the increased glucose levels of a rat model of diabetic nephropathy, and in patients with Fabry disease [11, 12]. Furthermore, recent studies indicate the intracellular degradation of collagen stimulated by TFG- β in kidneys is dependent upon autophagy-associated protein Beclin-1 [13]. Regulation of renal fibrosis and the clearance of immune complexes during inflammatory MPGN is potentially regulated through autophagy-associated pathways.

Renal disease due to glomerulonephritis and interstitial nephritis is a common clinical sign of visceral leishmaniasis due to *Leishmania infantum*, occurring in greater than 96% of symptomatic dogs and approximately 25-30% of human cases [14-20]. Alterations in renal function during active VL are generally reversible with anti-*Leishmania* therapy [19-21]. However, VL-associated kidney disease is progressive and without therapy can result in ESRD (approximately 1.5% of human cases, >25% canine cases) [19, 21, 22]. Previous reports regarding the pathophysiology of VL-associated renal disease are conflicting, with separate studies showing either the presence or absence of Immunoglobulin G (IgG) and complement protein C3 [23, 24]. In addition, previous characterizations of the subtype of MPGN have varied greatly [15, 16, 25]. Accurate assessment of VL-associated glomerular lesions early in their progression is essential to determining an efficacious treatment regimen and is also of prognostic value [26].

Inflammasomes are protein complexes that respond to a variety of cellular stressors as well as direct receptor-ligand interactions [27]. The Nod-like receptor protein 3 (NLRP3) is a well characterized inflammasome protein that responds to intracellular pathogen associated molecular patterns (PAMPs) and stress-related molecules [27]. NLRP3 responds to numerous PAMPs including lipopolysaccharide (LPS), muramyl-dipeptide (MDP), single

and double stranded bacterial RNA, and TLR 7/8 ligand R848 [28-32]. NLRP3 can also be activated through elevations in endogenous molecules, including ATP, urate crystals, other particulate matter, zymogen, and other bacterial pore-forming toxins [29, 33-35]. In the kidney, IL-1 β and IL-18 are key pro-inflammatory mediators of renal disease [36]. In addition, a single study demonstrate the activation of NLRP3 mediated glomerular injury stimulated by NAPDH oxidase activation [37]. Immune complex deposition within the subendothelial space and within the glomerular mesangium may drive pro-inflammatory podocyte and filtration apparatus injury through the activation of NLRP3.

This study characterized the lesions and type of glomerulonephritis associated with chronic infection with *Leishmania infantum*. These renal alterations, present both in symptomatic disease and prior to the onset of symptomatic disease, were primarily of a membranoproliferative type I, with subendothelial and mesangial electron dense deposits and endocapillary and mesangial proliferation. With symptomatic disease, lesions were associated with a higher rate of renal fibrosis and segmental glomerulosclerosis. Protein deposits during VL-associated GMN were composed of *Leishmania infantum* antigen, IgG, and complement protein C3. Furthermore, this study is the first, to our knowledge, to evaluate the association of LC3+ autophagy and NLRP3+ inflammasome activation with clinical stage of disease during MPGN. This data suggests a potential role for both NLRP3 and LC3+ autophagy during the pathogenesis of immune complex mediated renal disease and VL-associated MPGN.

MATERIALS AND METHODS

Animals - Study animals were enrolled for this study based on IFAT serology as previously described [38] and euthanized with owner's consent. Necropsies were performed by pathologists at Iowa State University College of Veterinary Medicine and at UFRN in Natal, Brazil. Full or partial necropsies were performed on each animal with gross evaluation and tissues harvested for histopathologic examination from each animal.

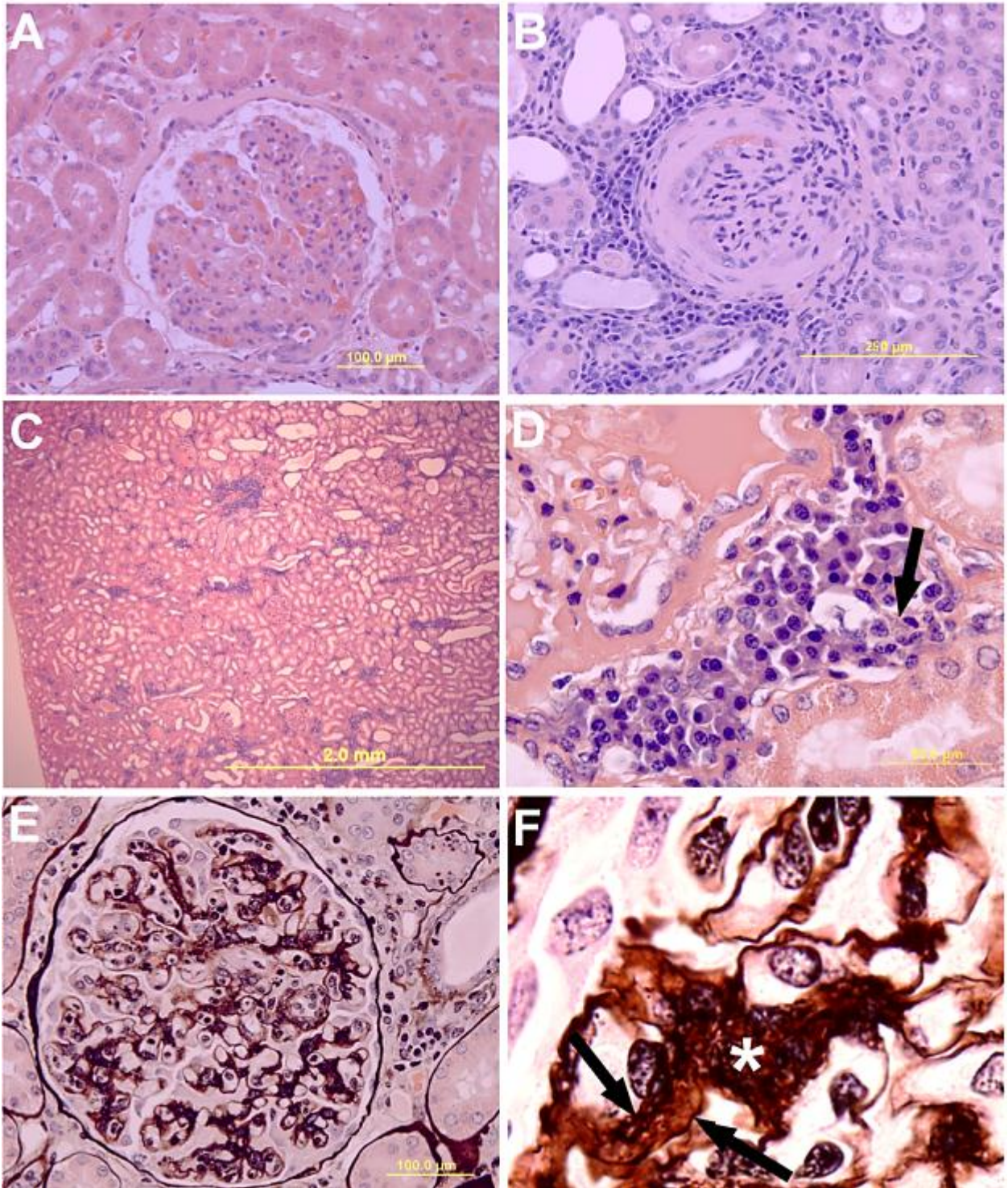
Histopathology - Tissues were fixed in 10% neutral buffered formalin, paraffin-embedded and processed for routine histopathologic evaluation. Sections were stained with hematoxylin and eosin (HE), Masson's trichrome, and periodic acid Schiff - methenamine silver (PASM). The sections were analyzed by light microscopy (BX41, Olympus), and the renal changes were classified according to the criteria of the World Health Organization for classification of the morphologic pattern of glomerulonephritis. Lesions were scored from Grade 1-4 based on expansion of the mesangium, mesangial fibrosis, prominence of capillary loops, periglomerular inflammation, and the percentage of sclerotic glomeruli.

Electron microscopy - Renal tissue was fixed in 2.0% glutaraldehyde in 0.1 M phosphate buffer, pH 7.4. Ultrathin sections were stained for analysis by transmission electron microscopy. 1 mm tissues were fixed in 2.5% glutaraldehyde in 0.1 M sodium cacodylate buffer. After fixation, samples were rinsed in cacodylate buffer, post-fixed in 2% osmium tetroxide, dehydrated in alcohols, cleared in propylene oxide and embedded in Eponate 12 epoxy resin. Ultrathin sections were cut, stained with uranyl acetate and lead citrate and examined with a Tecnai 12 G² electron microscope.

Immunohistochemistry – 3 micron sections were stained with the following antibodies at the indicated concentrations: poly-clonal canine anti-*L. infantum* (hyperimmune serum, 1:500 dilution), poly-clonal anti-canine IgG (2mg/ml, 1:6000 dilution) (Immunovision, Springdale, AZ, USA), poly-clonal anti-canine IgM (2mg/ml, 1:2000) (Immunovision, Springdale, AZ, USA), poly-clonal anti-canine C3b (1 mg/ml, 1:200 dilution) (Bethyl Labs, Montgomery, Texas) (2mg/ml). For IgG and IgM labeling, slides were pre-heated to 57°C for 30 minute prior to deparaffinization. Endogenous peroxidases were inhibited by addition of 3% H₂O₂ twice for 10 minutes, followed by 3 rinses in ultrapure water. Antigen retrieval was performed at 96°C in pH 10 Tris buffer for 5 minutes, followed by transfer into -20°C for 20 minutes. Samples were blocked with 10% normal goat serum in PBS for 20 minutes prior to primary antibody addition. Samples were washed and stained with multilink (Biogenex, Fremont, CA, USA) and developed with Streptavidin HRP and Nova Red (Vectorlabs, Burlingame, CA, USA) prior to counterstaining with hematoxylin. C3b staining was similar, but with antigen retrieval in Tris HCL pH 1 at 96°C for 20 minutes. Labeling for *Leishmania* antigen was performed as previously published [39]. Procedure was similar, but with primary antibody staining overnight at 4°C. Appropriate controls were included in each experiment.

Immunofluorescence - Formalin fixed paraffin-embedded sections and cryosections were labeled with poly-clonal canine cross-reactive anti-human LC3 (0.2 mg/ml, 1:50 dilution) (AbCam, Cambridge, MA), and poly-clonal canine cross-reactive anti-human NALP3 (0.5 mg/ml, 1:100 dilution) (AbCam, Cambridge, MA). Sections were washed and cryosections were fixed with Acetone for 5 minute then air dried for 30 minutes. Sections were then

Figure 3.1. Kidney sections from *L. infantum*-infected dogs evaluated for lesions associated with GMN. (A) Glomeruli were diffusely expanded by mesangial and endocapillary proliferation with hypersegmentation of the glomerular tuft and segmental thickening of Bowman's capsule. Hematoxylin and Eosin (HE, 400x). (B) Segmentally, renal glomeruli become sclerotic, with prominent lymphoplasmacytic and histiocytic interstitial nephritis, and fibrosis of Bowman's capsule and the glomerular tuft. HE (400x). (C) Interstitial nephritis with prominent multifocal peri-glomerular and perivascular accumulations of plasma cells, lymphocytes, and macrophages. HE (100x). (D) 1000x magnification of C. Multifocal peri-glomerular aggregates of plasma cells, lymphocytes, and macrophages, occasionally containing intracellular protozoal *Leishmania* (arrow). HE. (E) Glomeruli have a robust expansion of the mesangium with mesangial cell proliferation and interposition. Glomerular basement membranes commonly have splitting with double contours. PASM (400x). (F) 1000x magnification of mesangial cell interposition and expansion of the mesangium (asterisk), and double contours of the glomerular basement membrane (between arrows). PASM.



permeabilized with 0.3% Triton X 100 (Sigma) in 1x PBS for 10 minutes. Sections were then washed and treated with blocking immunofluorescence buffer (2% FCS, 1% BSA, 0.1% Tween 20 in 1x PBS) for 30 minutes prior to labeling with primary antibodies overnight at 4°C. Secondary antibodies for LC3 (Texas Red conjugated anti-rabbit IgG) and NLRP3 (Alexafluor 400 conjugated anti-goat IgG) were used at a concentration of 2 µg/ml for 60 minutes at room temperature. Coverslips were added using Prolong Gold Anti-fading Reagent (Life Technologies, Grand Island, NY USA) and analyzed via confocal microscopy. Secondary antibody and unstained controls were included for each experiment.

Image analysis – Glomeruli were imaged individually and analyzed with Image J using threshold analysis to calculate the percentage of glomerular area with positive staining, the number of positive cells as a percentage of total glomerular cells counted as DAPI-positive nuclei in fluorescent images, and density of positive staining.

Statistical analysis - Statistical analysis was conducted with one way ANOVA or pair-wise student's t-tests as appropriate conducted with Graph Pad Prism 5 with Tukey's post-test, statistical significance at $\alpha=0.05$.

RESULTS

VL-associated glomerulopathy lesions are present in asymptomatic animals, with GBM expansion and fibrosis associated with symptomatic disease.

To assess the onset of glomerular lesions and their association with symptomatic VL, we evaluated renal samples from 13 asymptomatic and 12 symptomatic dogs from the United States and Brazil diagnosed as infected with *Leishmania infantum*, and kidneys from five

non-renal disease control dogs presented to Iowa State University Department of Veterinary Pathology. Animals were staged prior to necropsy based on clinical presentation, including lymphadenopathy, palpable liver or spleen, and skin lesions typical of VL. The 15 dogs from the United States were also evaluated via full physical exam and fecal exam for co-

Table 3.1. Microscopic lesion summary of VL-associated glomerulopathy in dogs

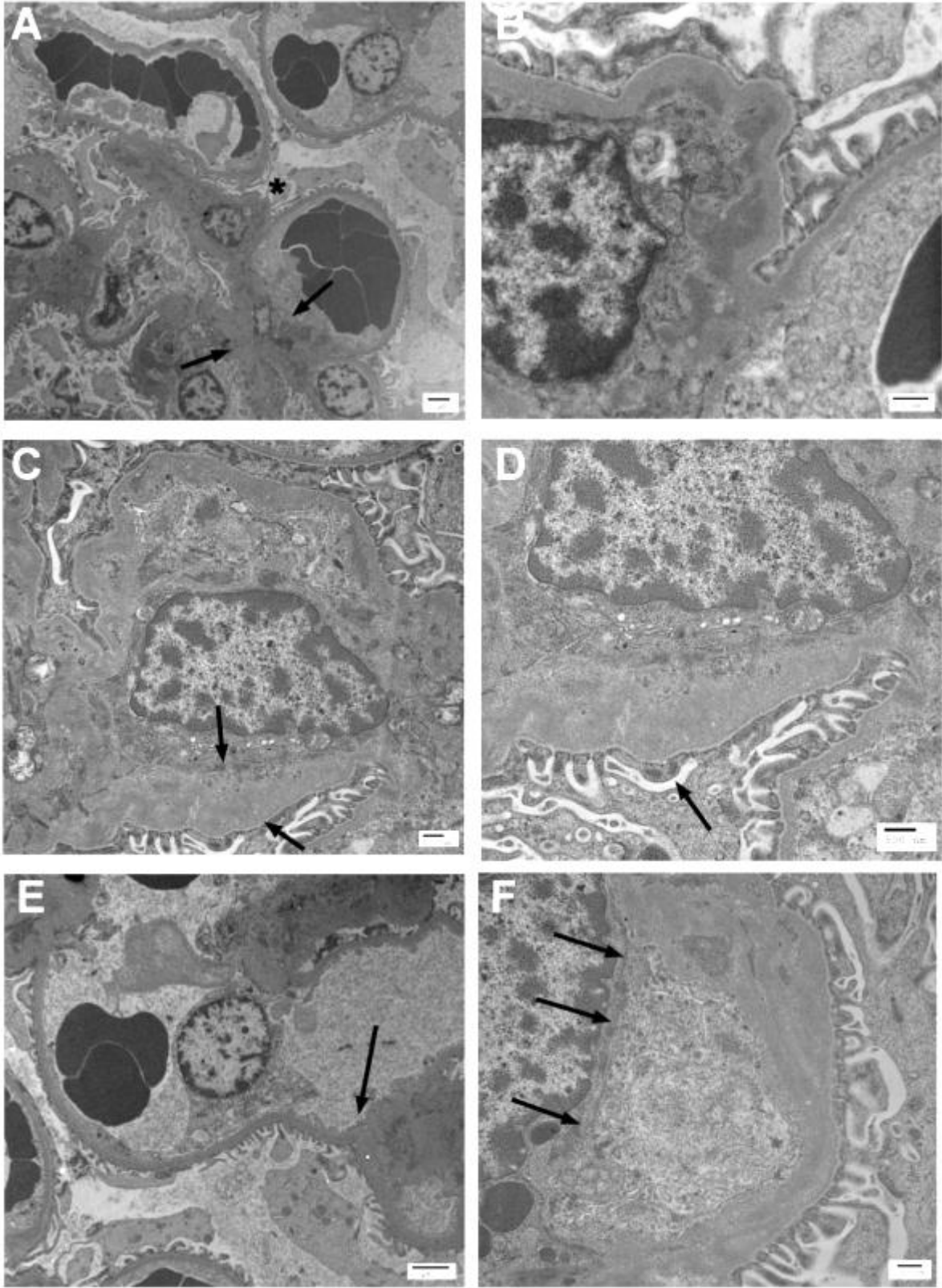
	Asymptomatic	Symptomatic	Total
Mesangial proliferation	92.31%, (12/13)	100.00%, (12/12)	96.00%, (24/25)
Interstitial nephritis	92.31%, (12/13)	91.67%, (11/12)	92.00%, (23/25)
Glomerular hypersegmentation	92.31%, (12/13)	100.00%, (12/12)	96.00%, (24/25)
Glomerular and interstitial fibrosis	7.69%, (1/13)	91.67%, (11/12)***	46.00%, (12/25)
Double contour GBM	15.38%, (2/13)	91.67%, (11/12)***	52.00%, (13/25)

***p<0.001

morbidities. The 10 dogs from Brazil were more likely to be symptomatic at the time of presentation (7/10), and may have had additional co-morbidities, including malnutrition, helminth infection, or rickettsial disease that were not present in the U.S. cohort.

Glomerular lesions were present at a high rate in both asymptomatic and symptomatic dogs. Ninety-six percent (24/25) of all dogs had hypercellularity within the glomerulus, based on routine histopathologic examination (Table 3.1, Figure 3.1A). Glomeruli were large and hypercellular, typical of mesangial cell and capillary endothelial proliferation (Figure 3.1A). Glomerular hypersegmentation, with a distinct lobular appearance of glomerular tufts,

Figure 3.2. Ultrastructural lesions of VL-associated glomerulonephritis are characteristic of Type I Membranoproliferative Glomerulonephritis. Renal cortical sections were harvested from dogs with symptomatic VL. Renal tissue was fixed in glutaraldehyde and analyzed via Transmission electron microscopy (A) Renal glomerular section with mesangial cell hypercellularity and mesangial cell capillary interposition (asterisk). Mesangial and subendothelial deposits were prominent (arrows). Transmission electron microscopy (4,320x). (B) 27,600x magnification of mesangial cell interposition. Podocyte foot processes were separated from the glomerular basement membrane by mesangial cell processes with the presence of electron dense material within both the GBM and mesangial cell. TEM (27,600x). (C) Prominent subendothelial deposits within the glomerular capillary, with segmental thickening of the GBM (between arrows). TEM (16,400x) (D) 27,600x magnification of segmental subendothelial thickening. Note the relative sparing of podocyte foot processes with only occasional blunting and fusion (arrow). TEM (27,600x) (E) Endocapillary hypercellularity with a plump and reactive endothelial cell with separation from the GBM by subendothelial deposits (arrow). TEM (7,160x). (F) 27,600x magnification of subendothelial deposits with interposed cellular processes separating the endothelial cell from the GBM. TEM (27,600x).



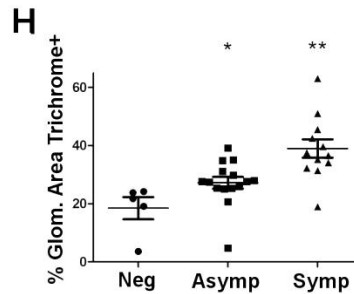
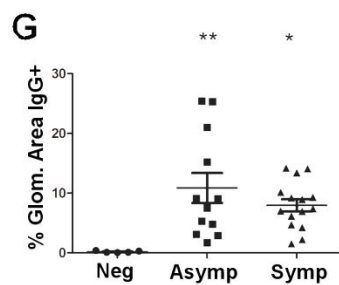
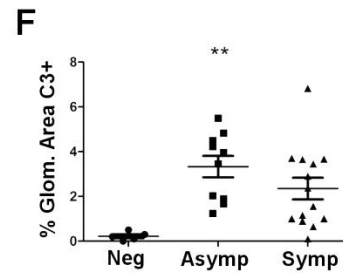
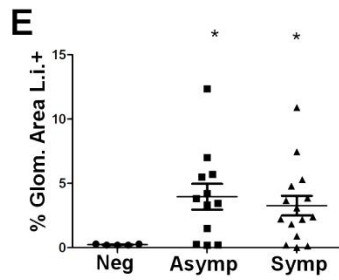
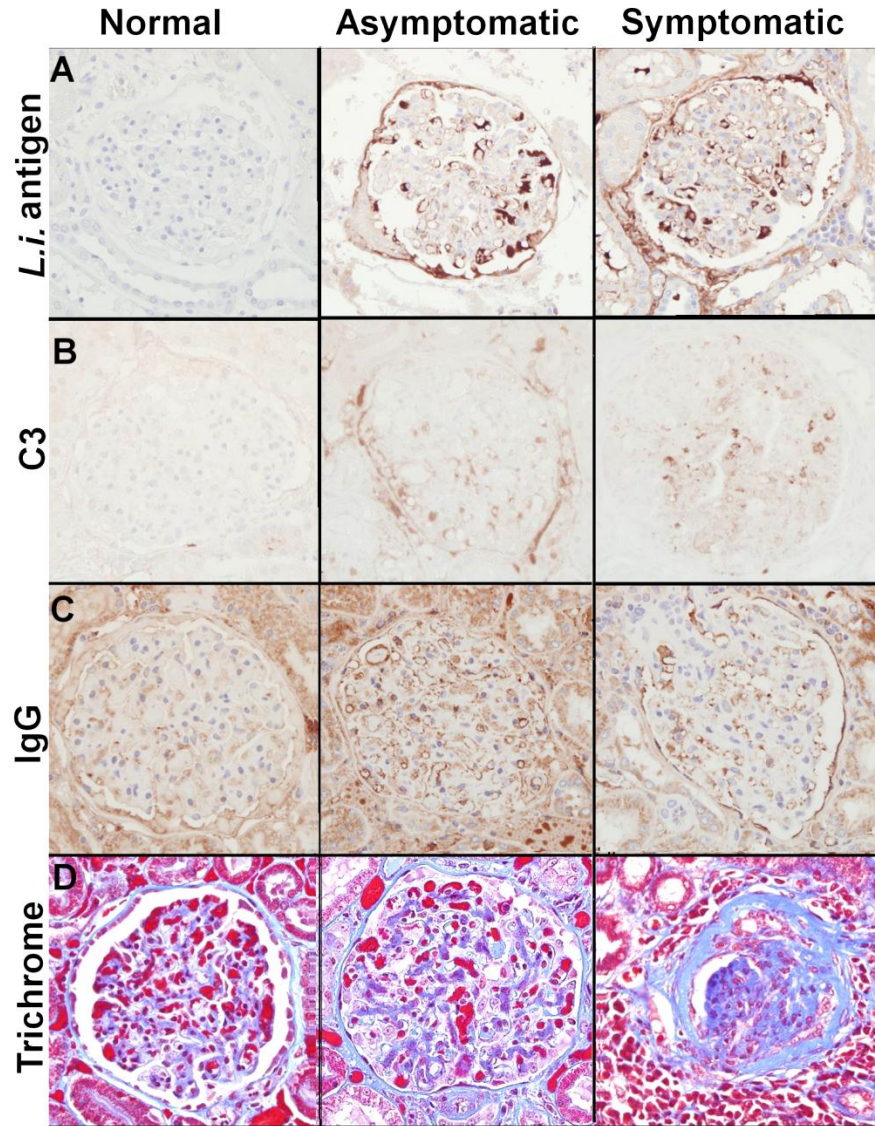
was also present at a high rate in both asymptomatic and symptomatic animals (96%, 24/25 total cases) (Table 3.1, Figure 3.1A). Interstitial nephritis, characterized by infiltration of macrophages, lymphocytes and plasma cells into peri-glomerular and peri-vascular areas was present equally in both asymptomatic and symptomatic dogs, at 92% of both experimental groups (Table 3.1, Figure 3.1C, D). Factors predictive of symptomatic disease were irreversible lesions typically associated with chronicity. Expansion of mesangial matrix with mesangial cell interposition (Figure 3.1, E, F asterisk) and segmental splitting of the glomerular basement membrane (Figure 3.1F, arrows) analyzed via periodic acid Schiff's – methanamine silver (PASM) stain was significantly increased within the symptomatic group (91.67%, 11/12) compared to the asymptomatic group (15.38%, 2/13) (OR=60.5, CI= 4.76, 769)(Table 3.1). The rate of glomerular and interstitial fibrosis measured via routine histopathology, was also significantly increased within the symptomatic group (91.67%, 11/12)(OR=132, CI=7.33, 2377) compared to the asymptomatic group (7.69%, 1/13) (Table 3.1, Figure 3.1B). These findings suggest that while membranoproliferative lesions were present both during asymptomatic and symptomatic VL. Lesions of chronicity, particularly fibrosis and expansion of mesangial matrix, were significantly associated with the presence of symptomatic VL.

Lesions of VL-associated glomerulonephritis are membranoproliferative type I.

Determination of membranoproliferative glomerulonephritis type is primarily based on ultrastructural evaluation of glomeruli [6]. The traditional WHO classification scheme for immune-mediated glomerulopathy utilized histopathologic and ultrastructural characteristics to classify lesions. as membranous (spiked dense protein accumulations within the GBM), and membranoproliferative (protein deposits within the GBM and mesangium driving

proliferation of mesangial cells, endocapillary proliferation, capillary remodeling, and mesangial cell interposition with duplication of glomerular basement membranes) [5]. Membranoproliferative glomerulonephritis is traditionally further classified as 1) MPGN Type I, with subendothelial and mesangial protein deposition, 2) MPGN Type II, with electron-dense intra-membranous and mesangial deposits, also known as dense deposit disease, or 3) MPGN Type III, with subendothelial, subepithelial, and/or complex deposits with fraying of the lamina densa [5]. These characterizations are however, based on morphology rather than specific cause, and can often be found a spectrum of changes within a single biopsy, or can differ by the clinical stage by a single causative agent. Previous reports of VL-associated glomerulonephritis identify lesions ranging from membranoproliferative in nature to end-stage renal disease with glomerulosclerosis [15, 16, 23-25, 40]. The ultrastructural changes evident in this study were subendothelial, intramembranous, and/or mesangial, with blunting and fusion of podocyte foot processes. In this study, we also found pronounced mesangial cell proliferation and interposition (Figure 3.2A, B asterisk), with primarily subendothelial and mesangial electron dense deposits (Figure 3.2A, C, D arrows). Remarkably, given the expansion of the glomerular basement membrane, podocyte foot processes were largely unaffected in asymptomatic cases, with only occasional fusion, and rare blunting and separation (Figure 3.2D, F). Endocapillary proliferation and endothelial separation from the glomerular basement membrane was pronounced in all cases (Figure 3.2E, F). The changes of subendothelial and mesangial electron dense deposits with mesangial cell interposition and endocapillary proliferation are consistent with membranoproliferative glomerulonephritis type I. The accurate characterization of glomerular lesions is becoming increasingly important, with the

Figure 3.3. VL-associated MPGN is the result of deposition of *Leishmania infantum* antigen, IgG, and C3. Formalin-fixed paraffin embedded renal cortical sections from dogs naturally infected with *Leishmania infantum* or negative controls were evaluated for endocapillary and mesangial deposits of *L. infantum* antigen (A), complement protein C3 (B), Immunoglobulin G (C), and for glomerular fibrosis (D). (A) *Leishmania infantum* antigen immunohistochemistry with hematoxylin counterstain. (B) C3 immunohistochemistry with hematoxylin counterstain. (C) Immunoglobulin G immunohistochemistry with hematoxylin counterstain. (D) Masson's trichrome staining for collagen. (E) The percentage of glomerular area staining positive for *L. infantum* antigen in normal controls, asymptomatic VL, and symptomatic VL, gated via threshold analysis in Image J. (F) The percentage of glomerular area staining positive for C3 in normal controls, asymptomatic VL, and symptomatic VL, gated via threshold analysis in Image J. (G) The percentage of glomerular area staining positive for IgG in normal controls, asymptomatic VL, and symptomatic VL, gated via threshold analysis in Image J. (H) All Images (A-D) were obtained at 400x magnification. The percentage of glomerular area staining positive for Trichrome (Collagen) in normal controls, asymptomatic VL, and symptomatic VL, gated via color threshold analysis in Image J. Data is presented as population graphs with SEM. Statistical analysis was performed using GraphPad Prism 5. Analysis was conducted via One-way ANOVA with Tukey's post-test, * $p < 0.05$, ** $p < 0.01$.

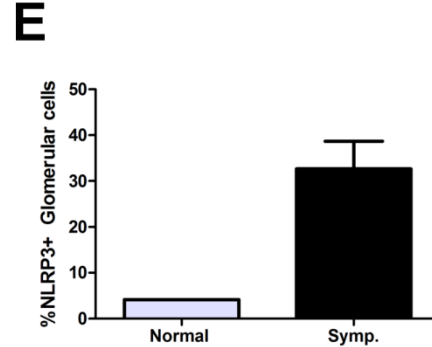
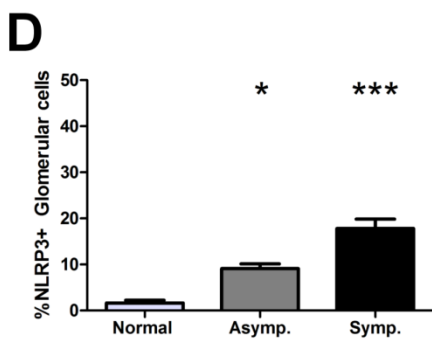
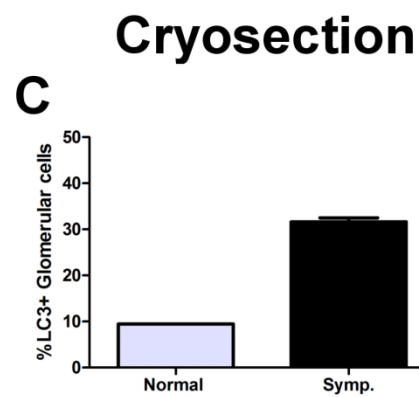
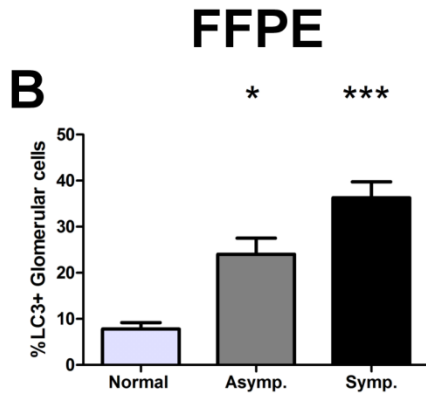
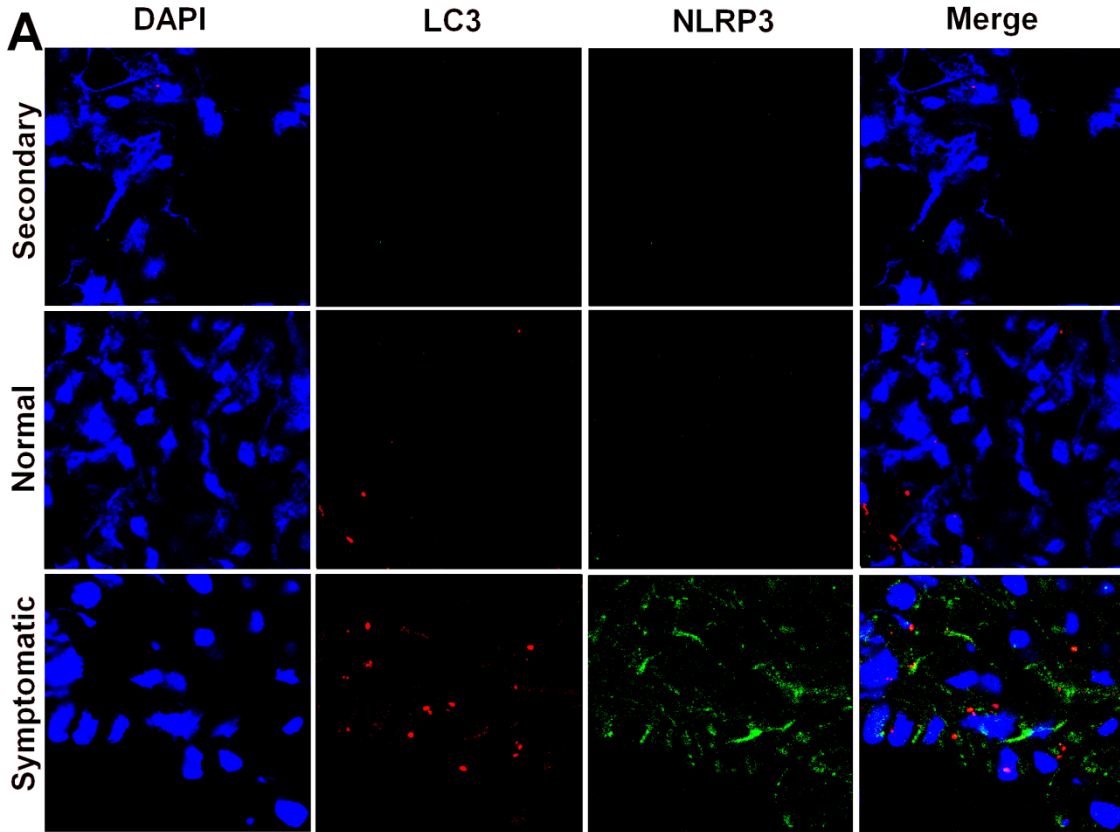


increasing number of randomized clinical trials evaluating targeted biotherapeutics, to address cases on an individualized basis [5]. Accurate typing is also prognostically valuable, with a documented 5 fold reduction in ESRD based on the extent of GBM and mesangial deposits and the severity of the glomerular lesions [26].

Glomerular basement membrane deposits are associated with complexes primarily composed of Leishmania antigen, IgG, complement protein C3b, and increased collagen.

New efforts to correlate the classification system for MPGN with clinical severity and therapeutic outcome, have led to reclassification of glomerular lesions based not only on the location of the deposits, but on the components of the electron dense deposits [5]. Previous reports of canine VL are conflicting; one demonstrated presence of *Leishmania* antigen, but absence of complement, IgG, or IgM, and another demonstrated presence of IgG, IgM, and C3 [23, 24]. In this study we evaluated the presence of IgG, IgM, C3, and *Leishmania* antigen in FFPE sections from asymptomatic and symptomatic animals. Glomeruli were imaged, and the area of the glomerular tuft quantified via mask creation in Image J. A threshold of positivity was created using color threshold analysis, and IHC positivity was quantified as area IHC positive staining as a percentage of total glomerular area. In both asymptomatic and symptomatic animals the level of labeling of *Leishmania* antigen was significantly elevated compared to the five control animals (Figure 3.3A, E). Labeling for IgG via immunohistochemistry was also significantly elevated as a percentage of glomerular area in both the asymptomatic and symptomatic groups compared to normal dogs (Figure 3.3C, G). There was no difference in IgM staining within the glomerulus between asymptomatic, symptomatic, or control dogs (data not shown). Immunohistochemical

Figure 3.4. VL-associated MPGN is associated with elevated vacuolar-associated LC-3 autophagy protein and the NLRP3 inflammasome. Frozen and/or formalin-fixed paraffin-embedded renal cortical sections were labeled with immunofluorescent antibodies and imaged and counted via confocal and immunofluorescence microscopy to evaluate the presence of LC3 positive autophagy-associated vacuoles and increased presence of NLRP3 positive inflammasomes. (A) Immunofluorescence of renal glomeruli from a secondary antibody control sample (top row), *L. infantum* negative dogs (second row), and dogs with symptomatic VL (bottom row). Cells were stained with DAPI, (left column), labeled for NLRP3 (anti-human polyclonal, Alexafluor 488, middle left), LC3 (anti-human polyclonal, Texas Red, middle right). (B, C) Population graphs of the percentage of LC3 positive cells as a percentage of total glomerular nucleated cells from *L. infantum* negative (B, C), asymptomatic (B), and symptomatic dogs (B, C) from formalin fixed paraffin-embedded (B) and frozen cryosections (C). (D, E) Population graphs of the percentage of NLRP3 positive cells as a percentage of total glomerular cells from *L. infantum* negative (D, E), asymptomatic (D), and symptomatic dogs (D, E) from formalin fixed paraffin-embedded sections (D) and frozen cryosections (E). Data was analyzed via one-way ANOVA with Tukey's post-test for significance. * $p < 0.05$, *** $p < 0.01$.



labeling of complement protein C3b was increased as a percentage of glomerular area in both asymptomatic and symptomatic dogs compared to control. Asymptomatic animals trended higher in C3b labeling than symptomatic animals but this was not statistically significant ($p=0.17$). This is consistent with presence of serum hypergammaglobulinemia in dogs with symptomatic leishmaniasis. Immunoglobulin G and *L. infantum* antigen deposits were present in asymptomatic dogs as well, suggesting deposition was associated with a mesangial and endocapillary proliferative response, and sub-endothelial deposits, but is present prior to the onset of symptomatic VL.

We also evaluated the degree of mesangial collagen and glomerular fibrosis via Masson's Trichrome. We utilized similar image analysis gating the color threshold on the blue staining typical of collagen. Trichrome-positive, collagen staining was increased in both the asymptomatic and symptomatic animals and symptomatic dogs had significantly greater staining of collagen than asymptomatic dogs (Figure 3.3D, H). This data indicates the degree of glomerular fibrosis is closely associated with the clinical status of *L. infantum* - infected dogs.

Increased NLRP3 is associated with clinical disease and glomerular inflammation.

Glomerular immune complex deposition and subsequent impairment of the glomerular filtration apparatus has been previously associated with numerous pro-inflammatory cytokines, including IL-1 β with fibrosis stimulated by TGF β [37, 41]. Previous reports of VL-associated glomerulonephritis demonstrated increased expression of the adhesion molecules such as ICAM and P-Selectin [23]. Numerous stimuli can result in NLRP3 inflammasome activation in renal tubular epithelium, including uric acid crystals,

amyloid, cholesterol crystals, and high glucose [33, 35, 42]. This activates caspase 1-mediated IL-1 β production. To evaluate the possibility that the inflammasome protein NLRP3 was associated with the progression of VL-associated MPGN, we labeled formalin-fixed paraffin embedded sections (Figure 3.4D) and cryosections (Figure 3.4A, E) with immunofluorescence for NLRP3 (Figure 3.4, column 3, D, E). NLRP3 positivity was significantly elevated in symptomatic dogs compared to normal dogs (Figure 3.4A, column 3, D, E).. NLRP3 was typically present within the cellular cytoplasm, as fine punctate cytoplasmic staining either near the cell periphery or diffusely throughout the cell cytoplasm, and occasionally within vacuolar structures. This data suggests an association between NLRP3 inflammasome induction and the severity of renal disease due to *Leishmania infantum*. This could be causative or the result of prolonged pro-inflammatory and antigen stimulation within the glomerulus.

Autophagy protein LC3 is associated with symptomatic infection with L. infantum.

Macroautophagy is an integral component of organelle and protein recycling within cells, with the most abundant macroautophagy in long-lived cells of the body including neurons, cardiomyocytes, and glomerular podocytes, and within metabolically active cells such as skeletal muscle and renal tubular epithelium. The importance of macroautophagy in podocyte maintenance of the glomerular filtration apparatus has been previously demonstrated in podocin-conditional LC3 knockout mice [7]. These mice develop protein-losing nephropathy and eventual glomerulosclerosis due to the accumulation of poly-ubiquitinated protein with death by 24 weeks of age [7]. In macrophages, the autophagy machinery can also be engaged in response to pathogen-associated molecules, including

immune complexes [43]. To evaluate if increased LC3 was associated with the precipitation of clinical renal disease and the onset of identifiable MPGN due to VL, we labeled formalin-fixed paraffin-embedded (Figure 3.4 B, C) or frozen cryosections (Figure 3.4A, C) from the renal cortex for LC3, then quantified LC3+ cells as a percentage of total glomerular cells from *L. infantum* negative, asymptomatic, and symptomatic dogs. The percentage of glomerular cells with LC3+ compartments was significantly elevated in symptomatic dogs compared to control animals (Figure 3.4A, B, C). Interestingly, labeling for LC3 and NLRP3 was segmental within glomeruli, consistent with the segmental deposits demonstrated by TEM. As a percentage of total glomerular cells LC3 and NLRP3 were consistently elevated in glomeruli of all stages of lesion severity, including those with a robust proliferative mesangium and those with a higher degree of collagen and fibrosis (data not shown). This data demonstrates a strong association between the relative presence of LC3+ compartments within the glomerulus, the severity of MPGN due to VL, and symptomatic VL. This increase could be the result of increased cellular stress and the subsequent recycling of cellular organelles or a direct result of immune complex, complement, and antigen deposition within the glomerular mesangium and subendothelial region of the glomerular basement membrane.

DISCUSSION

Chronic kidney disease is a major global health problem, for which approximately 5% of all health care expenditures are utilized [2-4]. This largely is the result of therapy for end stage renal disease (ESRD) including long-term dialysis and renal transplantation. Renal disease was also the ninth leading cause of death in the United States in 2010, with approximately 50,406 fatalities [44]. The incidence of kidney disease and associated

mortality has increased steadily since 1980 in the United States, and is higher in developing regions with high rates of hepatitis C-associated glomerulonephritis and relatively lower access to dialysis and renal transplantation [1]. Even so, the physiology of the glomerulus including specific responses of glomerular podocytes and mesangial cells, are incompletely understood. These cells, in conjunction with vascular endothelial cells, form and maintain the glomerular filtration apparatus responsible for filtration of 20% of the body's volume of blood with each heartbeat. An understanding of the molecular pathophysiology of glomerulonephritis will lead to novel therapeutics and diagnostics for intervention and early recognition of renal disease, reducing the need for costly treatment of ESRD and the overall need for renal transplantation.

Renal disease is a common clinical complication of human and canine VL. Nearly 100% of clinically effected dogs have renal lesions and approximately 30% of overall human cases with a rate of acute kidney injury in children of approximately 25-45.9% [14-20]. These lesions are largely responsive to therapy with antimonials or amphotericin B [20, 21, 45]. However, approximately 1.5% of patients present with renal failure [19]. Renal lesions in both humans and dogs due to visceral leishmaniasis have been previously characterized as progressive glomerulonephritis including mesangial proliferative, membranoproliferative, focal segmental glomerulosclerosis, and minimal change glomerulonephritis, and a smaller percentage with crescentic glomerulonephritis [16, 23, 24, 40]. These morphologic classifications may be largely indicative of the chronicity of glomerular injury, but have little correlation with the mechanism of pathologic insult or the glomerular response to said insult. In our study, every classification of glomerulonephritis could be found in individual glomeruli from the same renal cortical section in some cases. Recent efforts to expand the

WHO classification model to include a molecular characterization of the glomerular deposits in addition to routine histologic evaluation and electron microscopy have added additional information regarding the pathogenesis of specific forms of glomerulonephritis [5]. This provides guidance for targeted therapeutics and may elucidate molecular targets for therapy to reduce long-term renal insufficiency and ESRD.

In this study, we characterized the primary morphologic changes associated with VL-associated glomerulonephritis and the molecular components of the glomerular deposits characteristic of VL glomerulonephritis. We have classified VL-associated glomerulonephritis as membranoproliferative type I glomerulonephritis, associated with segmental subendothelial and mesangial deposits of *L. infantum* antigen, IgG, and complement protein C3. Furthermore, our study utilized VL-associated glomerulonephritis as a model to evaluate the association of macroautophagy marker LC3 and NLRP3 with symptomatic disease and the severity of glomerular lesions. This study indicated LC3+ compartments and NLRP3 protein indicative of the NLRP3 inflammasome are significantly increased during asymptomatic and symptomatic VL compared to controls. Macroautophagy in response to immune complex deposition within the glomerulus may be a major mechanism for removal of accumulated proteins, complement, and immune complexes from the glomerular filtration slit. NLRP3 activation in response to immune complex deposition is a possible source for increased IL-1 β and IL-18 within the kidney, which serves as an important chemotactic and pro-inflammatory stimulus.

Multiple studies have evaluated the morphology and ultrastructural characteristics of renal lesions due to VL in dogs and humans [16, 20, 23, 24, 46]. Previous characterizations described a wide array of morphologic changes, primarily of a membranoproliferative and

mesangial proliferative type [16, 20, 23, 24, 46]. Dogs with symptomatic VL typically have a hypergammaglobulinemia and a high degree of circulating parasite antigen [38]. It is logical that immune complexes comprise glomerular deposits responsible for VL-associated MPGN. However, studies evaluating the proteins associated with these glomerular deposits have had conflicting results [23, 25]. One study in dogs from the island of Elba found granular deposits of IgG, IgM, and C3 within 31 of 34 dogs examined [25]. However, a similar study conducted in Brazil found no difference between infected and control dogs in the degree of IgG, IgM, or C3 [23]. The latter study did however find a significant increase in the amount of *L. infantum* antigen and inflammatory cells within the GBM and mesangium [23]. Our study demonstrates a significant increase in granular to segmental deposits of IgG, C3, and *L. infantum* antigen within both the GBM and mesangium, with no accumulation of IgM. Disparities between studies are possibly due to the stage and severity of disease in the animal cohorts. One segment of the cohort used in our study was from a prospective United States cohort of dogs studied from 2007 until the present. Animals in this cohort, even though symptomatic, are likely to be identified and euthanized at an earlier stage of disease, prior to severe fibrosis and glomerulosclerosis. This may have an impact on the type and density of deposits present and the morphologic characteristics of the glomerular lesions.

The cytokines IL-1 β and IL-18 are major pro-inflammatory cytokines correlated with inflammatory renal disease and reperfusion injury in the kidney after ischemia [36]. Renal tubular cells are known to secrete IL-1 β and IL-18 in response to tubulointerstitial inflammation, driving pro-inflammation [36, 47, 48]. This type of inflammation, if present within the glomerulus, could be a mechanism for inflammatory cell recruitment and significant pro-inflammatory damage to the glomerular filtration apparatus. The role of

inflammasome activation in the glomerulus during naturally-occurring infection induced MPGN is unknown. Two studies in murine experimental models that have evaluated NLRP3 activation within the glomerulus give opposite results. A single study of the activation of the NLRP3 inflammasome during a murine model of anti-GBM disease found little expression of NLRP3 mRNA, caspase 1 mRNA, or pro-IL-1 β and found renal glomeruli incapable of producing NLRP3, caspase 1 protein, or IL-1 β [49]. However, two other studies have demonstrated not only that NLRP3 is expressed by glomerular podocytes, but that NADPH oxidase induced NLRP3 inflammasome activation, driving caspase-1, and triggering podocyte injury [37]. There have been no other studies, to our knowledge, evaluating the role of NLRP3 in glomerular disease, and no previous reports of the presence of NLRP3 positivity during MPGN. Our study is the first, to our knowledge to associate glomerular NLRP3 with the severity of renal lesions and symptomatic MPGN. NLRP3 is a possible contributor to glomerular pathology and a possible therapeutic target for inflammatory renal disease.

Long-lived and metabolically active cells utilize pathways of macroautophagy (self-eating) for recycling of cellular components via sequestration into double membrane autophagosomes with subsequent lysosomal fusion, degradation, and recycling. A related form of autophagy, xenophagy, results in uptake and degradation of numerous bacterial, viral, and protozoal pathogens utilizing component of the autophagy machinery, and is thought to be essential for the immune response to these pathogens [50]. The role of autophagosomes in these cases seems to be to target microbial products to pattern recognition receptor bearing compartments, and to facilitate eventual antigen presentation via MHC II [51]. Non-canonical autophagy (or LC3-associate phagocytosis) proceeds in the absence of

canonical pathway proteins ULK-1 and FIP 200 in response to stimulation through a class III PI₃K and dependent upon autophagy complex proteins Beclin 1, ATG5, and ATG 7 [52-54]. This pathway has been demonstrated to be initiated in response to Fc gamma receptor engagement by immune complexes, and stimulates NADPH oxidase production in macrophages [43]. The formation of LC3-II from LC3-I into its autophagosomal membrane-associated form, results in a pattern of immunofluorescent staining of discrete puncta, indicative of autophagosomes formation [50]. In this study, we have demonstrated for the first time the association of renal lesion and disease severity and elevated glomerular autophagy in infectious disease-related MPGN. A single previous study has correlated the presence of increased autophagosomes with IgA nephropathy patients, and multiple studies have evaluated the role of autophagy for glomerular homeostasis [7, 8, 10, 13]. Elevated autophagy has also been identified in a rat model of diabetic nephropathy in response to elevated levels of blood glucose [11]. This study is consistent with previous findings and elucidates a potential role for glomerular autophagy in response to immune complex deposition within the glomerulus.

Recent studies suggest that the NLRP3 inflammasome may be induced in response to NADPH oxidase in glomerular podocytes and that non-canonical autophagy mediated through Beclin 1 is integral to podocyte homeostasis [7, 43]. Macrophages can induce NADPH oxidase after engagement of Fc gamma receptor by immune complexes [43]. It is possible that the processing of glomerular immune complex deposits is mediated through an autophagy pathway and that this process stimulates the induction of IL-1 β via the NLRP3 inflammasome and NADPH oxidase. However, this study is cross-sectional, and therefore the results should be evaluated as such. Detailed experimental models may further elucidate

these mechanisms. The strong associations presented within this naturally occurring model of MPGN are highly suggestive of a role for glomerular inflammasome activation and autophagy in either the induction of or response to glomerular deposition of immune complexes and antigen. Therapeutic targeting of these molecules may have potential to limit long-term renal damage during MPGN.

ACKNOWLEDGEMENTS

We would like to thank the Iowa State University Histopathology Laboratory for their technical expertise and assistance with this study. We would like to specifically thank Deborah Moore, Diane Gerjets, and Jack Gallup for their additional technical assistance. We would also like to thank Dr. Katherine Gibson-Corely for her contribution in archival samples for this study.

REFERENCES

1. **Eckardt, K., and Kasiske, B.L.,** *KDIGO clinical practice guidelines for glomerulonephritis*. Kidney International supplements, 2010. **2**(2).
2. **Eknoyan, G., et al.,** *The burden of kidney disease: improving global outcomes*. Kidney Int, 2004. **66**(4): p. 1310-4.
3. CDC. *Chronic Kidney Disease Initiative: Protecting Kidney Health*. 2012 [cited.
4. *Prevalence of chronic kidney disease and associated risk factors--United States, 1999-2004*. MMWR Morb Mortal Wkly Rep, 2007. **56**(8): p. 161-5.
5. **Bomback, A.S. and G.B. Appel,** *Pathogenesis of the C3 glomerulopathies and reclassification of MPGN*. Nat Rev Nephrol, 2012. **8**(11): p. 634-42.

6. **Sethi, S. and F.C. Fervenza**, *Membranoproliferative glomerulonephritis--a new look at an old entity*. N Engl J Med, 2012. **366**(12): p. 1119-31.
7. **Hartleben, B., et al.**, *Autophagy influences glomerular disease susceptibility and maintains podocyte homeostasis in aging mice*. J Clin Invest, 2010. **120**(4): p. 1084-96.
8. **Sato, S., et al.**, *Correlation of autophagy type in podocytes with histopathological diagnosis of IgA nephropathy*. Pathobiology, 2009. **76**(5): p. 221-6.
9. **Sato, S., et al.**, *Autophagy by podocytes in renal biopsy specimens*. J Nihon Med Sch, 2006. **73**(2): p. 52-3.
10. **Sato, S., et al.**, *Two types of autophagy in the podocytes in renal biopsy specimens: ultrastructural study*. J Submicrosc Cytol Pathol, 2006. **38**(2-3): p. 167-74.
11. **Ma, T., et al.**, *High glucose induces autophagy in podocytes*. Exp Cell Res, 2013. **319**(6): p. 779-89.
12. **Chevrier, M., et al.**, *Autophagosome maturation is impaired in Fabry disease*. Autophagy, 2010. **6**(5): p. 589-99.
13. **Kim, S.I., et al.**, *Autophagy promotes intracellular degradation of type I collagen induced by transforming growth factor (TGF)-beta1*. J Biol Chem, 2012. **287**(15): p. 11677-88.
14. **T, D.E.B., et al.**, *Glomerular involvement in human kala-azar. A light, immunofluorescent, and electron microscopic study based on kidney biopsies*. Am J Trop Med Hyg, 1975. **24**(1): p. 9-18.
15. **Benderitter, T., et al.**, *Glomerulonephritis in dogs with canine leishmaniasis*. Ann Trop Med Parasitol, 1988. **82**(4): p. 335-41.
16. **Costa, F.A., et al.**, *Histopathologic patterns of nephropathy in naturally acquired canine visceral leishmaniasis*. Vet Pathol, 2003. **40**(6): p. 677-84.
17. **Zatelli, A., et al.**, *Glomerular lesions in dogs infected with Leishmania organisms*. Am J Vet Res, 2003. **64**(5): p. 558-61.
18. **Rocha, N.A., et al.**, *Visceral leishmaniasis in children: a cohort of 120 patients in a metropolitan city of Brazil*. Turk J Pediatr, 2011. **53**(2): p. 154-60.

19. **Liborio, A.B., et al.**, *Acute kidney injury in children with visceral leishmaniasis*. *Pediatr Infect Dis J*, 2012. **31**(5): p. 451-4.
20. **Dutra, M., et al.**, *Renal involvement in visceral leishmaniasis*. *Am J Kidney Dis*, 1985. **6**(1): p. 22-7.
21. **Ikeda-Garcia, F.A., et al.**, *Evaluation of renal and hepatic functions in dogs naturally infected by visceral leishmaniasis submitted to treatment with meglumine antimoniate*. *Res Vet Sci*, 2007. **83**(1): p. 105-8.
22. **Plevraki, K., et al.**, *Effects of allopurinol treatment on the progression of chronic nephritis in Canine leishmaniosis (Leishmania infantum)*. *J Vet Intern Med*, 2006. **20**(2): p. 228-33.
23. **Costa, F.A., et al.**, *T cells, adhesion molecules and modulation of apoptosis in visceral leishmaniasis glomerulonephritis*. *BMC Infect Dis*, 2010. **10**: p. 112.
24. **Poli, A., et al.**, *Renal involvement in canine leishmaniasis. A light-microscopic, immunohistochemical and electron-microscopic study*. *Nephron*, 1991. **57**(4): p. 444-52.
25. **Nieto, C.G., et al.**, *Pathological changes in kidneys of dogs with natural Leishmania infection*. *Vet Parasitol*, 1992. **45**(1-2): p. 33-47.
26. **Vikse, B.E., et al.**, *Prognostic factors in mesangioproliferative glomerulonephritis*. *Nephrol Dial Transplant*, 2002. **17**(9): p. 1603-13.
27. **Strowig, T., et al.**, *Inflammasomes in health and disease*. *Nature*, 2012. **481**(7381): p. 278-86.
28. **Gross, O., et al.**, *Syk kinase signalling couples to the Nlrp3 inflammasome for anti-fungal host defence*. *Nature*, 2009. **459**(7245): p. 433-6.
29. **Mariathasan, S., et al.**, *Cryopyrin activates the inflammasome in response to toxins and ATP*. *Nature*, 2006. **440**(7081): p. 228-32.
30. **Craven, R.R., et al.**, *Staphylococcus aureus alpha-hemolysin activates the NLRP3-inflammasome in human and mouse monocytic cells*. *PLoS One*, 2009. **4**(10): p. e7446.
31. **Kanneganti, T.D., et al.**, *Critical role for Cryopyrin/Nalp3 in activation of caspase-1 in response to viral infection and double-stranded RNA*. *J Biol Chem*, 2006. **281**(48): p. 36560-8.

32. **Muruve, D.A., et al.**, *The inflammasome recognizes cytosolic microbial and host DNA and triggers an innate immune response*. *Nature*, 2008. **452**(7183): p. 103-7.
33. **Dostert, C., et al.**, *Innate immune activation through Nalp3 inflammasome sensing of asbestos and silica*. *Science*, 2008. **320**(5876): p. 674-7.
34. **Petrilli, V., et al.**, *Activation of the NALP3 inflammasome is triggered by low intracellular potassium concentration*. *Cell Death Differ*, 2007. **14**(9): p. 1583-9.
35. **Martinon, F., et al.**, *Gout-associated uric acid crystals activate the NALP3 inflammasome*. *Nature*, 2006. **440**(7081): p. 237-41.
36. **Anders, H.J. and D.A. Muruve**, *The inflammasomes in kidney disease*. *J Am Soc Nephrol*, 2011. **22**(6): p. 1007-18.
37. **Abais, J.M., et al.**, *NADPH Oxidase-Mediated Triggering of Inflammasome Activation in Mouse Podocytes and Glomeruli During Hyperhomocysteinemia*. *Antioxid Redox Signal*, 2012.
38. **Boggiatto, P.M., et al.**, *Immunologic indicators of clinical progression during canine Leishmania infantum infection*. *Clin Vaccine Immunol*, 2010. **17**(2): p. 267-73.
39. **Gibson-Corley, K.N., et al.**, *Disseminated Leishmania infantum infection in two sibling foxhounds due to possible vertical transmission*. *Can Vet J*, 2008. **49**(10): p. 1005-8.
40. **Sayari, M., R. Avizeh, and F. Barati**, *Microscopic evaluation of renal changes in experimental canine visceral leishmaniosis after chemo- and immunotherapy*. *Pak J Biol Sci*, 2008. **11**(12): p. 1630-3.
41. **Lopez-Hernandez, F.J. and J.M. Lopez-Novoa**, *Role of TGF-beta in chronic kidney disease: an integration of tubular, glomerular and vascular effects*. *Cell Tissue Res*, 2012. **347**(1): p. 141-54.
42. **Chen, K., et al.**, *ATP-P2X4 signaling mediates NLRP3 inflammasome activation: A novel pathway of diabetic nephropathy*. *Int J Biochem Cell Biol*, 2013. **45**(5): p. 932-943.
43. **Henault, J., et al.**, *Noncanonical autophagy is required for type I interferon secretion in response to DNA-immune complexes*. *Immunity*, 2012. **37**(6): p. 986-97.
44. **Hoyert, D.L., and Xu J.**, *Deaths: Preliminary Data for 2011*. *National Vital Statistics Reports*, 2012. **61**(6).

45. **Beltrame, A., et al.**, *Acute renal failure due to visceral leishmaniasis by Leishmania infantum successfully treated with a single high dose of liposomal amphotericin B*. J Travel Med, 2008. **15**(5): p. 358-60.
46. **Costa, F.A., et al.**, *CD4(+) T cells participate in the nephropathy of canine visceral leishmaniasis*. Braz J Med Biol Res, 2000. **33**(12): p. 1455-8.
47. **Vilaysane, A., et al.**, *The NLRP3 inflammasome promotes renal inflammation and contributes to CKD*. J Am Soc Nephrol, 2010. **21**(10): p. 1732-44.
48. **Timoshanko, J.R., et al.**, *Contributions of IL-1beta and IL-1alpha to crescentic glomerulonephritis in mice*. J Am Soc Nephrol, 2004. **15**(4): p. 910-8.
49. **Lichtnekert, J., et al.**, *Anti-GBM glomerulonephritis involves IL-1 but is independent of NLRP3/ASC inflammasome-mediated activation of caspase-1*. PLoS One, 2011. **6**(10): p. e26778.
50. **Choi, A.M., S.W. Ryter, and B. Levine**, *Autophagy in human health and disease*. N Engl J Med, 2013. **368**(7): p. 651-62.
51. **Munz, C.**, *Antigen Processing for MHC Class II Presentation via Autophagy*. Front Immunol, 2012. **3**: p. 9.
52. **Sanjuan, M.A., et al.**, *Toll-like receptor signalling in macrophages links the autophagy pathway to phagocytosis*. Nature, 2007. **450**(7173): p. 1253-7.
53. **Martinez, J., et al.**, *Microtubule-associated protein 1 light chain 3 alpha (LC3)-associated phagocytosis is required for the efficient clearance of dead cells*. Proc Natl Acad Sci U S A. **108**(42): p. 17396-401.
54. **Florey, O., et al.**, *Autophagy machinery mediates macroendocytic processing and entotic cell death by targeting single membranes*. Nat Cell Biol, 2011. **13**(11): p. 1335-43.

CHAPTER 4

**IMMUNOGENICITY OF A POLYPEPTIDE VACCINE FOR CANINE
VISCERAL LEISHMANIASIS**

Authors: Esch, K.J.¹, Martinez, P.A.¹, Juelsgaard, R.¹, Shimak, R.¹, Schafbuch, R.¹, Mull, S.¹, Jones, D.E.¹, Duthie, M.S.², Howard, R.F.², Grosenbaugh, D.³, Fischer, L.⁴, Reed, S.G.², Petersen, C.A.^{1*}

¹Department of Veterinary Pathology, College of Veterinary Medicine, Iowa State University, Ames, IA, ²Infectious Disease Research Institute, Seattle, WA, ³Merial Ltd, Athens, GA, ⁴Merial S.A.S, Lyon, France

An article to be submitted to the journal Veterinary Immunology and Immunopathology

ABSTRACT

Leishmania infantum is a vector-borne obligate intracellular protozoal parasite that infects both humans and dogs. The domestic dog is a major reservoir for human infection. As such, a vaccine that would prevent transmission between dogs or humans would have a significant veterinary and public health impact. Current vaccination strategies for *L. infantum* control in dogs have shown only moderate efficacy and less-than-palatable vaccine site reactions with use of saponin-based adjuvants. To improve upon these previous vaccines, in the present study we compared four vaccine modalities based on a synthetic poly-protein antigen, *Leishmania* Vaccine Antigen A (LVAA), with a novel highly immunogenic TLR-

agonist adjuvant, GLA-SE. Thirty dogs, randomized into 5 experimental groups (n=6/group), were immunized to evaluate the immunogenicity and safety of vaccine modalities based on LVAA at time 0 (prime) and day 21 (boost). Peripheral blood mononuclear cells from dogs vaccinated with Ad:Pox had significant proliferation and a significant number of cells producing IFN γ in both CD4+ and CD8+ T cell populations upon re-exposure to LVAA protein compared to PBMC responses from other groups. LVAA vaccination did not induce a significant increase in IL-10 from PBMC of dogs in any group. These data suggest that LVAA is a strongly immunogenic and safe vaccine candidate for use against visceral leishmaniasis in dogs. Our findings revealed that the Ad:Pox platform was the optimal vaccine platform for robust IFN γ production and T-cell proliferation, signatures of a T helper 1 response. Further investigation of this candidate vaccine should be pursued to determine its clinical potential in dogs.

INTRODUCTION

Disease causing *Leishmania* species are endemic in 98 countries and 3 territories, accounting for approximately 2 million human cases and 20-40,000 deaths annually [1]. *L. infantum* causes significant morbidity and mortality in dogs, the predominant domestic reservoir of human disease, with canine seroprevalence in areas of Brazil ranging up to 40% [1, 2]. Development of an immune response capable of clearing *Leishmania spp.* infection is dependent upon a timely and pronounced Th1 response [3]. Correlates of this response are IL-12 production by dendritic cells and macrophages with subsequent presentation of parasite antigen on MHC II and CD4+ lymphocyte stimulation toward proliferation and production of IFN γ , with limited production of the Th2-associated or regulatory cytokines

IL-4 and IL-10 [4, 5]. In this study we evaluate CD4+ and CD8+ T cell proliferation, IFN γ , and IL-10 intracellular expression and production as a recall response to both vaccine and whole freeze-thawed *L. infantum* antigen (f-t *L.i.*) as probable correlates of protective immunity.

Current treatment for leishmaniasis primarily uses combinations of a number of chemotherapeutic agents. Pentavalent antimonial agents have been widely used as a first-line treatment for VL for decades, and this is reflected by recent increases in antimonial resistance [6]. Pentavalent antimony is frequently used in conjunction with allopurinol. Amphotericin B is a widely available polyene anti-fungal drug considered the drug of choice in areas with antimonial resistance [7]. These two drugs have high rates of severe adverse effects and extensive injection-based treatment regimens [8, 9]. Newer formulations of amphotericin B into a liposomal form (AmBisome®) has proven to be effective with a single dose, but is highly expensive for use in endemic regions [7, 10]. While this and other improved chemotherapeutic regimens are in development, recrudescence of disease occurs in greater than 65% of dogs following effective chemotherapy [11]. Global management of VL in humans and animals may require novel vaccine approaches to develop long-term immunity.

Vaccination for cutaneous leishmaniasis has a centuries-old history, traditionally called Leishmanization (LZ), using a small amount of exudate from an infected individual to inoculate uninfected persons in an inconspicuous location [12, 13]. This means of *Leishmania* prevention can be quite effective, but the quality control of such approaches is greatly deficient [14, 15]. The use of cultured promastigotes for live vaccination is also challenging as *Leishmania* species lose virulence quickly after passage in culture, and thus

generate less than optimal host immunity. Whole-killed parasites with adjuvants have been used in vaccination trials with poor efficacy [16]. Gene-deletion live vaccines have also been pursued with some potential. Centrin-deleted, replication-deficient *L. donovani* was effective in prevention of infection with a challenge exposure to virulent *L. donovani* in BALB/c and SCID mice and in susceptible Syrian golden hamsters [17, 18].

One of the only approved canine vaccines in Brazil contains a fucose-mannose ligand of *L. donovani* with saponin adjuvant; resulting in an approximate reduction in clinical disease by 60-75% after 2 years [19, 20]. Another canine vaccine, Leish-Tec®, utilized adenovirus expression of the A2 amastigote antigen [21, 22]. Second-generation vaccines such as Leish-110f (L110f) and other vaccine candidates, are based on using a combination of highly immunogenic peptides linked into fusion proteins and administered with adjuvants targeted to TLR4 (MPLA or GLA) or TLR9 (CpG DNA) [23, 24]. Most have demonstrated protective efficacy in BALB/c mice but, under the conditions tested, were not as effective as previously healed infection at preventing *Leishmania major* infection via sandfly in C57/B6 mice [25, 26]. A version of L110f, MML, was combined with MPL, tested in dogs, and found to be effective in small-scale studies. At the relatively high dose tested in a larger two-year study, MML was minimally effective in preventing clinical disease as scored and defined for that study [27]. L110f with MPL used as immunotherapy with dogs was more effective with 90% improvement in clinical signs with 100% of unvaccinated controls having no improvement or death by 6 months [28].

Vaccination approaches to develop protective immunity against *Leishmania* spp. have been particularly challenging because of immune modulation at the site of infection mediated both by the parasite and by the saliva of the sandfly vector [29]. Research into the effects of

sandfly saliva in inoculation sites demonstrates an early influx of neutrophils that rapidly phagocytize but do not kill the parasite, impairing and skewing the local dendritic cell and macrophage response. In addition, parasite-induced alterations in cell signaling results in improper dendritic cell maturation and decreased production of IL-12, a key pro-inflammatory mediator, through enhanced phosphorylation of ERK signaling from the phagosome [30]. Therefore, successful immunity may be difficult to achieve through simply driving a T helper type 1 response. New approaches to vaccination with improved long-term cell-mediated memory responses, improvements in quality control, and a reduction in adverse events are needed for prevention of both canine and human VL. An additional challenge may also be that in some instances dogs are not infected by sand fly, but via maternal, vertical transmission, presenting disease during the time of immune system maturation [31].

This study evaluates the immunogenicity of a novel *Leishmania* antigen candidate, *Leishmania* vaccine antigen A (LVAA), based on various modes of activation of the immune system in healthy dogs. We will demonstrate that LVAA stimulates a Th1-focused memory response capable of a significant recall response up to 2 weeks after vaccine boost across multiple vaccine modalities. While vaccination with either an adenovirus vector LVAA with protein boost or a adenovirus vector LVAA with canary pox vector LVAA boost induced cell-mediated recall responses, we found that adenovirus vector LVAA with canary pox vector LVAA boost provided the most pronounced memory response, including cellular proliferation, IFN γ production, and low IL-10. These data demonstrate that LVAA has a strong potential for canine vaccination against *L. infantum*.

MATERIALS AND METHODS

Sample Population and Study Enrollment – One-year-old female beagles with no prior exposure to *L. infantum* or infected sand flies, housed at Iowa State University, were acclimated prior to study initiation. Study animals had complete veterinary standard of care, including monitoring throughout the study by licensed veterinarians. Vaccinations were administered by licensed veterinarians via single subcutaneous injection, with the exception of the DNA vaccine preparation that was administered via intra-muscular injection. Twenty milliliters of blood was collected from each dog prior to vaccination and weekly after booster vaccination at days 0, 21, 28, 35, and 54. Procedures were performed with approval from Iowa State University Institutional Animal Care and Use Committee (IACUC).

Experimental Design and Vaccination Protocol – Dogs were randomized two per enclosure with adequate space. Dogs in three enclosures (n=6), were arbitrarily assigned to one of the following five experimental groups: 1) placebo (day 0) with placebo boost (day 21) (Control), 2) DNA LVAA vaccination (day 0) with LVAA protein boost (day 21) (DNA: Protein), 3) LVAA protein with GLA (TLR4 agonist) with LVAA protein and GLA boost (day 21) (Protein: Protein), 4) LVAA protein expressed by an adenoviral vector (day 0) with LVAA protein/GLA adjuvant boost (Day 21) (Ad:Protein), and 5) Adenovirus vector LVAA with LVAA expressed within a canary pox LVAA vector boost (day 21) (Ad:Pox).

Vaccine and Adjuvants – Vaccine A antigen in multiple preparations was prepared under the proprietary methods of Merial® Animal Health, and GLA adjuvant was prepared separately

by the Infectious Disease Research Institute (IDRI) and mixed immediately prior to vaccine administration.

Adverse event monitoring – Injection sites were measured via manual examination and caliper and examined clinically at 6, 24, 48, and 72 hours post-vaccination. Reactions were characterized by size, location, inflammation, and induration. These findings were then documented and localized reactions (of which there was only one) were photographed for documentation.

Sample Handling and PBMC Isolation - Whole blood samples separated into PBMC as previously described [32]. Whole blood samples collected in heparin-containing tubes were diluted 1:1 with 1x Hank's Buffered Salt Solution (Cellgro, Manassas, VA) and 25mM HEPES . Diluted whole blood was centrifuged at 800 rcf (Eppendorf, Hauppauge, NY) for 30 minutes at room temperature through Ficoll/Histopaque 1077 (Sigma Aldrich, St. Louis, MO) as previously described [32]. PBMC were counted with an automated cell counter (Beckman Coulter, Brea, CA). PBMC were washed twice in phosphate-buffered saline (PBS) and suspended in complete medium (CTCM) (RPMI 1640 supplemented with 10% fetal bovine serum, 100 U/ml penicillin, 100 µg/ml streptomycin, 2 mM l-glutamine, and 25 mM HEPES buffer). PMBC were counted and adjusted to 4×10^6 /ml for further analysis. Cells were then split for evaluation of proliferation and intracellular staining for flow cytometry, Griess, or ELISpot Assays.

Preparation of parasites and antigen stimulation - *L. infantum* (LIVT-2) grown for use as positive control for kqRT-PCR or freeze-thaw antigen (f-t *L.i.*) as previously described [32]. *L. infantum* (LIVT-2) was grown in complete Grace's medium (incomplete Grace's supplemented with 20% fetal bovine serum, 100 U/ml penicillin, 100 µg/ml streptomycin, and 2 mM l-glutamine). Parasites were harvested, pelleted at 2500 x g for 15 min at 4°C, washed twice with phosphate-buffered salt solution (PBS), and resuspended in PBS to 10⁷ parasites/ml. Parasites were then flash frozen in liquid nitrogen with subsequent thawing in a 37° water bath for 3 cycles of freeze-thaw. Whole f-t *L. infantum* antigen was quantified to 1 mg/ml protein concentration via BCA assay (Pierce, Rockford, IL) prior to dilution for antigen stimulation.

PBMC Antigen Stimulation - Cells were stimulated with Concanavalin A (ConA; 5 µg/ml) for 4 days, f-t *L.i.* (10 µg/ml) for 7 days, Vaccine A antigen (10 µg/ml) for 7 days, and distemper virus vaccine (Pfizer, Kalamazoo, MI), a non-*Leishmania*, antigen-specific, proliferation control (NSC) for 10 days. 24 hours prior to cell harvest, 5-ethynyl-2'-deoxyuridine (EdU) (Invitrogen, Grand Island, NY) was added at 10 µM, and 10 µg/ml brefeldin A (Sigma, St. Louis, MO) was added 6 hours before harvest. Cells were harvested and washed prior to surface and intracellular labeling.

PBMC immunolabeling – PBMC were labeled with EdU/AF488 for proliferation, CD4, CD8, and canine-specific intracellular IFN-γ and IL-10. Cells were blocked with 25 µl of canine serum, with mouse and rat non-specific polyclonal IgG at 20 µg/10⁶ PBMC for 20 minutes at 4°C prior to surface receptor labeling. After cell membrane receptor labeling, PBMC were

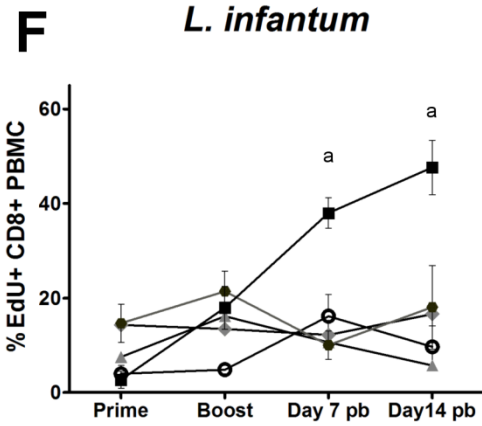
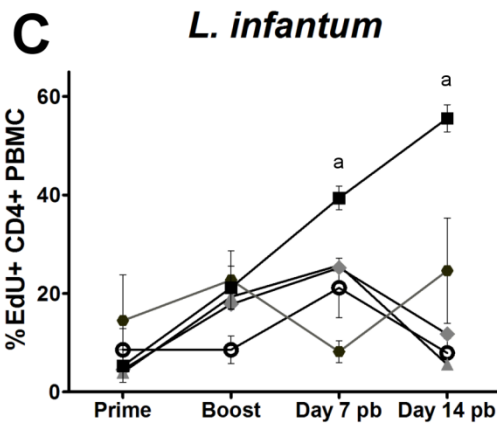
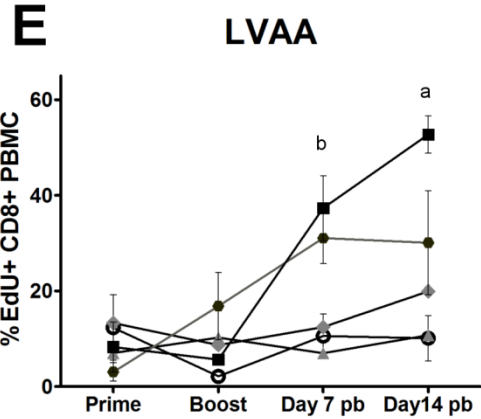
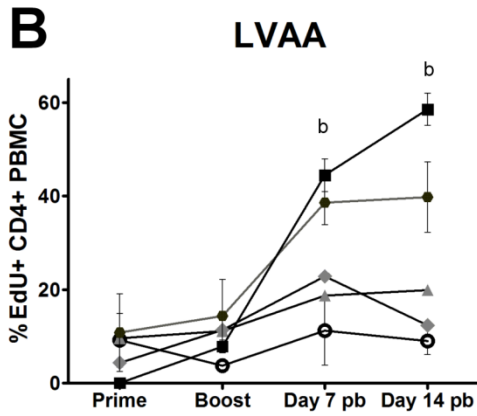
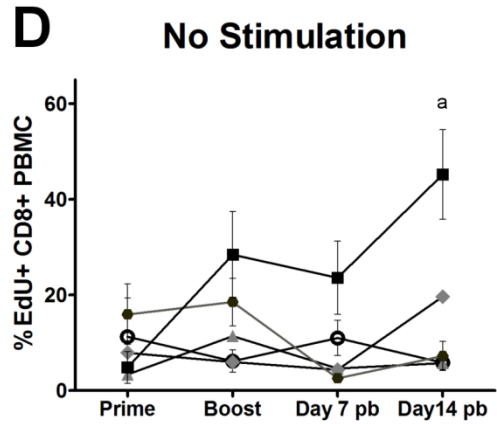
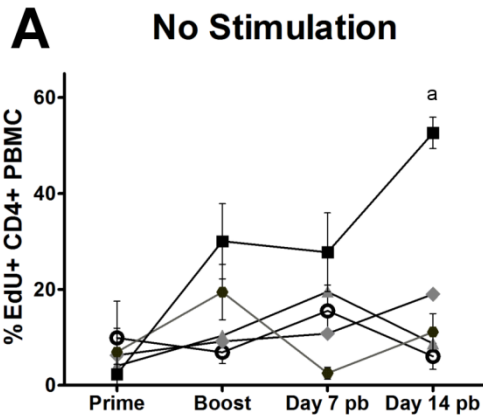
fixed with 1% paraformaldehyde, then permeabilized with saponin permeabilization reagent prior to intracellular cytokine labeling (Invitrogen, Grand Island, NY). PBMC were preserved in BD stabilizing fixative (BD biosciences, San Jose, CA) and analyzed within 48 hours. Data was acquired via FACScanto (BD biosciences, San Jose, CA) with FlowJo (TreeStar Inc., Ashland, OR). Canine PBMC labeling panel: EdU Click-It (Invitrogen, Grand Island, NY), anti-canine CD4/Alexafluor 647 (AbD Serotec, Raleigh, NC), anti-canine CD8/Alexafluor 700 (AbD Serotec, Raleigh, NC), anti-canine IFN γ /Zenon R-PE (R&D systems, Minneapolis, MN)(Invitrogen, Grand Island, NY), anti-canine IL-10/Zenon APC/Alexafluor 750 (R&D systems, Minneapolis, MN) (Invitrogen, Grand Island, NY), and anti-human biotinylated PD-1/PE-Cy7 streptavidin (R&D systems, Minneapolis, MN) (eBioscience, San Diego, CA).

ELISpot- PBMC were incubated on plates pre-coated with 500 ng anti-canine IFN γ or IL-10 capture antibody (R&D systems, Minneapolis, MN). Cells were plated in duplicate with 4, 2-fold dilutions starting at 5×10^5 PBMC/well. Cells were stimulated with 10 $\mu\text{g/ml}$ f-t *L. infantum* antigen or 10 $\mu\text{g/ml}$ canine distemper antigen (Pfizer, Kalamazoo, MI) overnight at 37°C and 5% CO₂. One hundred μl biotinylated detection antibody (R&D systems, Minneapolis, MN) was added at 0.5 $\mu\text{g/ml}$ and incubated overnight at 4°C. Detection was accomplished via streptavidin alkaline phosphatase and 5-bromo-4-chloro-3-indolyphosphate (BCIP) (Sigma Aldrich, St. Louis, MO). Spots were counted as an average between duplicate wells then as an average over all 4 dilutions, standardized to the number of spots per 10^6 PBMC. All counts were performed with complete blinding.

Figure 4.1. Vaccination with LVAA with Adenovirus vector and Canarypox vector boost induced CD4+ and CD8+ T cell proliferation after antigen stimulation. PBMC were collected from naïve (day 0) and previously primed (Day21; Boost), or previously boosted (Day7 pb, Day14 pb) laboratory dogs and stimulated with media (no stimulation, top row), 10 µg/ml of LVAA vaccine antigen (LVAA, middle row), or 10 µg/ml whole f-t *L. infantum* antigen (*L. infantum*, bottom row) for 7 days. Proliferation was measured via 24 hour uptake of EdU. **A-C** CD4+ T cell proliferation post-stimulation to no stimulation (**A**), LVAA (**B**), and f-t *L.i.* (**C**) **D-F** CD8+ T cell proliferation post-stimulation to no stimulation (**D**), LVAA (**E**), and f-t *L.i.* (**F**). Data was analyzed with GraphPad Prism 5 via 2-way ANOVA of all treatments over repeated time points with Bonferroni post-test. All graphs are shown as population data with error bars as SEM. Statistical analysis: a – Ad:Pox group significant over all other treatments ($p < 0.01$); b – Ad:Pox and Ad:Protein significant over all other groups ($\text{Ad:Pox} < 0.01$; $\text{Ad:Protein} < 0.05$).

CD4+ PBMC

CD8+ PBMC



- Adenovirus: Pox
- Adenovirus: Protein
- ◆ DNA: Protein
- ▲ Protein: Protein
- ⊖ Control

Nitric oxide production – The concentration of nitrite was assessed by the Griess reaction, in which 50 μ l cell culture supernatant and Griess reagent (LabChem, Pittsburgh, PA) was mixed and incubated at RT. The absorbance was measured at 550nm via microplate reader (Molecular Devices, Sunnyvale, CA). Nitrite concentration was determined via a sodium nitrite standard curve.

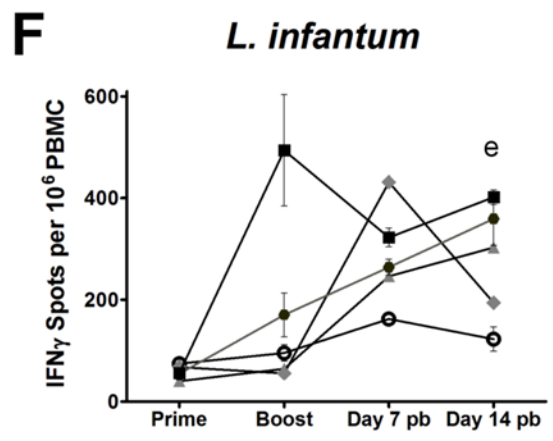
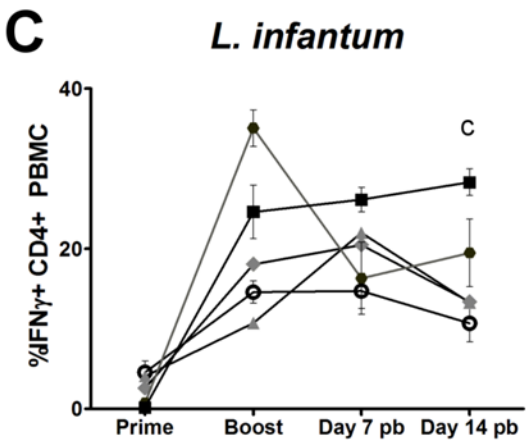
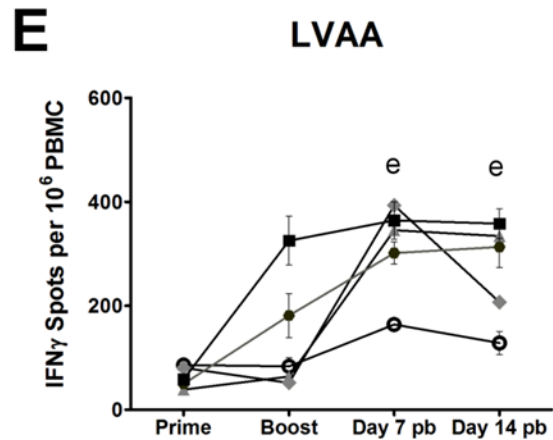
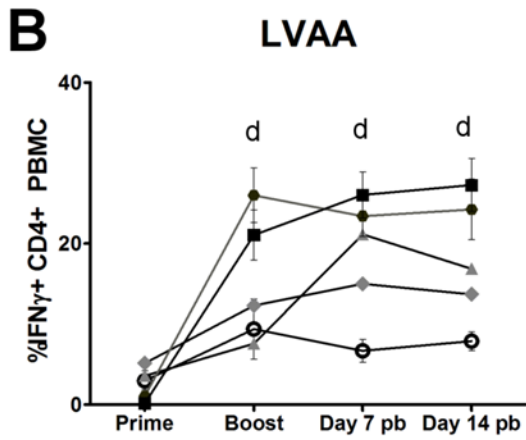
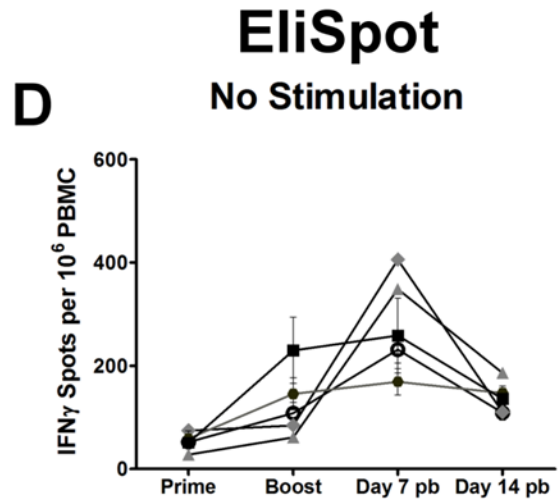
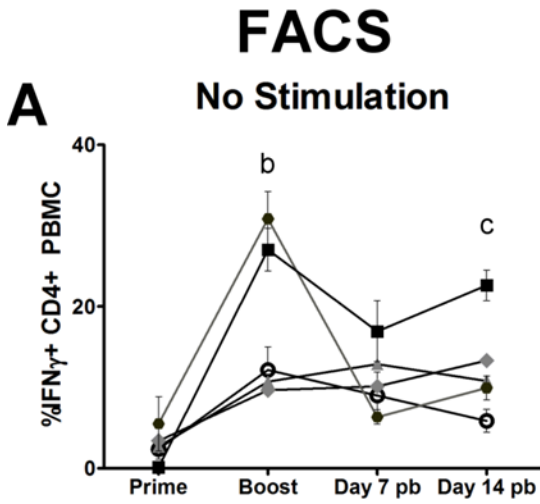
Statistical analysis – Statistical analysis was conducted with one way ANOVA with Bonferoni's post-test for multiple time points via Graph Pad Prism version 5.04 (GraphPad Software, La Jolla, CA), significance at $\alpha=0.05$. Graphical data presented as arithmetic mean \pm SEM.

RESULTS

LVAA induces pronounced proliferative response in CD4+ and CD8+ T cells

To evaluate how well LVAA administered through different modes of immune activation induced a T-cell recall response, we exposed PBMC from vaccinated dogs to both LVAA antigen and whole freeze-thawed *L. infantum* (ft-*L.i.*) antigen at multiple time points and evaluated proliferation as measured by EdU incorporation in CD4+ or CD8+ cells (Figure 4.1). No experimental group had a proliferative CD4+ or CD8+ T cell recall response to either LVAA or ft-*L.i.* at day 0 or at the time of boost vaccination at day 21. After boost, however, both groups with primary adenovirus vector vaccination (Ad:Protein, Ad:Pox) had significantly increased proliferation of CD4+ T cells by day 7 post-boost in response to LVAA antigen (Figure 4.1B). This proliferative response was most pronounced at day 14 post-boost (Figure 4.1B). The CD8+ T cell response to LVAA was similar, with both the

Figure 4.2. Vaccination with LVAA preparations induced significant CD4+ T cell intracellular and PBMC secretion of IFN γ . PBMC were collected from naïve (day 0) and previously primed (Day21; Boost), or previously boosted (Day7 pb, Day14 pb) laboratory dogs and stimulated with media (no stimulation, top row), 10 μ g/ml of LVAA vaccine antigen (LVAA, middle row), or 10 μ g/ml whole f-t *L. infantum* antigen (*L. infantum*, bottom row) for 24 hours (ELISpot) or 7 days (FACS). **A-C** Intracellular IFN γ within CD4+ PBMC after 7 days of stimulation with no stimulation (**A**), LVAA (**B**), or f-t *L.i.* (**C**). **D-F** Secretion of IFN γ after 24 hours of culture with no stimulation (**D**), LVAA (**E**), or f-t *L.i.* (**F**) in total PBMC measured via ELISpot. Data was analyzed with GraphPad Prism 5 via 2-way ANOVA of all treatments over repeated time points with Bonferroni post-test. All graphs are shown as population data with error bars as SEM. Statistical analysis: b - Ad:Pox and Ad:Protein significant over all other groups (Ad:Pox<0.01; Ad:Protein<0.05); c – Ad:Pox significantly increased over control (p<0.01); d - Ad:Pox and Ad:Protein significant over control (Ad:Pox<0.01; Ad:Protein<0.05); e – All vaccination groups significantly elevated over control (Ad:Pox (p<0.01), DNA:Protein, Protein:Protein, and Ad:Protein (p<0.05)).



- Adenovirus: Pox
- Adenovirus: Protein
- ◆ DNA: Protein
- ▲ Protein: Protein
- ⊖ Control

Ad:Protein and Ad:Pox groups having significant CD8⁺ T cell proliferation at day 7 post-boost, and only the Ad:Pox having significant proliferation by day 14 post-boost (Figure 4.1E). Overall proliferative responses to whole *f-t L.i.* were only significantly increased in the Ad:Pox group in both CD4⁺ and CD8⁺ T cells (Figure 4.1C, F). Interestingly, within the Ad:Pox group, CD4⁺ and CD8⁺ T cells from peripheral blood were undergoing a significant degree of proliferation in culture even in the absence of added antigen by day 14 post-boost (4.1A, D). This increase in proliferation within the no stimulation group occurs by day 14 post-boost, occurs in all animals of the Ad:Pox group in both CD4⁺ and CD8⁺ T cells, and is consistent with IFN γ production from this experimental group (Figure 4.2A). This appears to be associated with a response to the canarypox vector boost after adenovirus priming. Possible explanations for this response are prolonged antigen presentation, or survival of the viral vector within cells capable of antigen presentation longer-term after administration [33]. With non-specific stimulation subtracted out, the only group with significant antigen-specific proliferation was the Ad:Protein group ($P < 0.01$) within the CD4⁺ T cell population (Figure 4.1 A, B, C).

The adenoviral-vectored preparation, both with protein boost and canary pox-vector boost, was capable of proliferative recall responses to previous vaccination. Vaccination with adenovirus-vector LVAA with canary pox-vector LVAA boost generates the most robust overall proliferative recall response to vaccine antigen and whole *L. infantum* antigens. In addition, the Ad:Protein vaccination platform for LVAA generates the most robust antigen-specific population at 7 and 14 days post-boost.

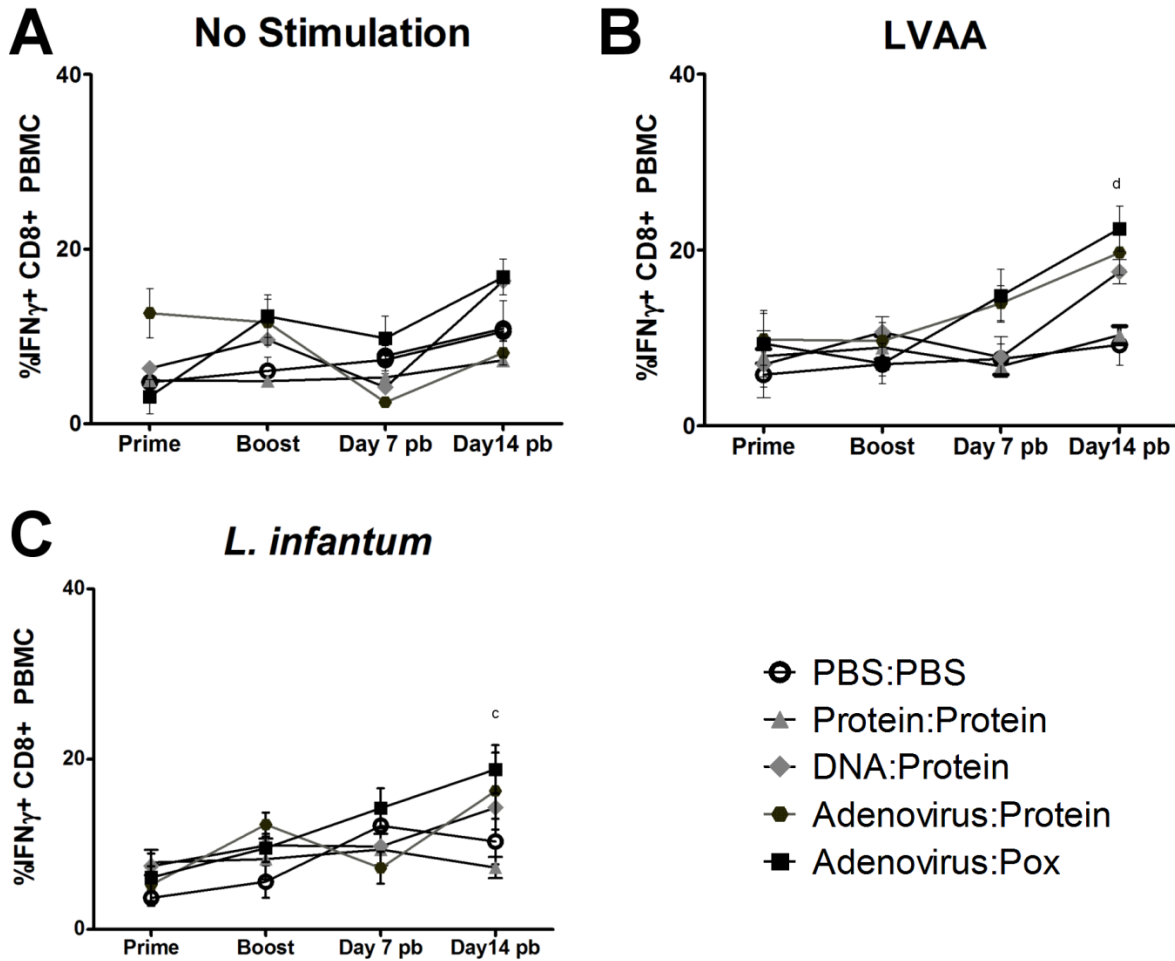


Figure 4.3. Vaccination with LVAA preparations induced significant CD8+ T cell intracellular IFN γ production. PBMC were collected from naïve (day 0) and previously primed (Day21; Boost), or previously boosted (Day7 pb, Day14 pb) laboratory dogs and stimulated with media (no stimulation, **A**), 10 $\mu\text{g/ml}$ of LVAA vaccine antigen (LVAA, **B**), or 10 $\mu\text{g/ml}$ whole f-t *L. infantum* antigen (*L. infantum*, **C**) 7 days. **A-C**) Intracellular IFN γ within CD8+ PBMC after 7 days of stimulation with no stimulation (**A**), LVAA (**B**), or f-t *L.i.* (**C**). Data was analyzed with GraphPad Prism 5 via 2-way ANOVA of all treatments over repeated time points with Bonferroni post-test. All graphs are shown as population data with error bars as SEM. Statistical analysis: c – Ad:Pox significantly increased over control ($p < 0.01$); d - Ad:Pox and Ad:Protein significant over control (Ad:Pox < 0.01 ; Ad:Protein < 0.05).

LVAA vaccine preparations promote IFN γ in CD4⁺ and CD8⁺ T cells

Protective immunity against *L. infantum* infection is requisite upon a robust Th1 type response characterized by pronounced levels of IFN γ from primarily CD4⁺ and CD8⁺ T cells. To evaluate the potential Th1 response in dogs vaccinated with LVAA, we monitored recall responses in PBMC from dogs vaccinated with LVAA by stimulating PBMC with f-t *L.i.* and LVAA for 7 days in vitro, then evaluating the number of CD4⁺ and CD8⁺ IFN γ ⁺ T cells. Both Ad:Protein and Ad:Pox groups had significantly elevated populations of IFN γ ⁺ CD4⁺ T cells compared to other groups in response to LVAA antigen at day 21 pre-boost, day 7 post-boost, and day 14 post-boost vaccination (Figure 4.2B). Significant increases at 21 days after primary vaccination occurred in both adenovirus-vector primed groups indicating that this vaccine formulation generated an IFN γ response after a single vaccination (Figure 4.2B). In response to whole f-t *L.i.*, only the Ad:Pox group demonstrated significant increases in IFN γ at day 14 post-boost (Figure 4.2C). Similar to cellular proliferation, there was a significant increase in IFN γ ⁺ CD4⁺ T cells within the no stimulation group of the Ad:Pox, primarily at day 14 post-boost. Antigen-specific proliferation after subtraction of the no stimulation group was significantly elevated in the Ad:Protein group at 7 and 14 post-boost ($p < 0.01$) and in the Protein:Protein group at day 7 post-boost ($p < 0.05$) (Figure 4.2A, B, C).

The secretion of IFN γ in response to antigen was evaluated for LVAA and f-t *L.i.* in PBMC from vaccinated and control animals using ELISpot to quantify the number of IFN γ -secreting cells per 10⁶ PBMC. These results demonstrated a significant increase in IFN γ production within both the Ad:Protein group and the Ad:Pox group over all other experimental groups day 21 pre-boost, day 7 post-boost, and day 35 post-boost, similar to

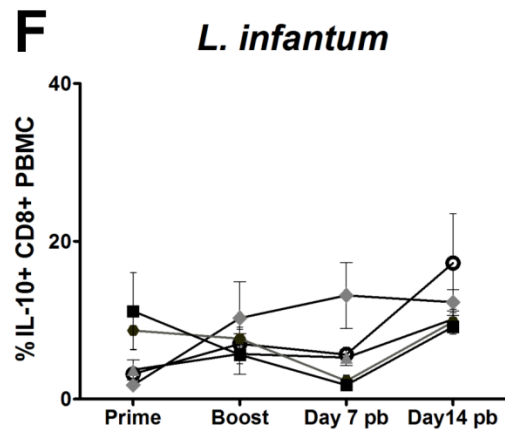
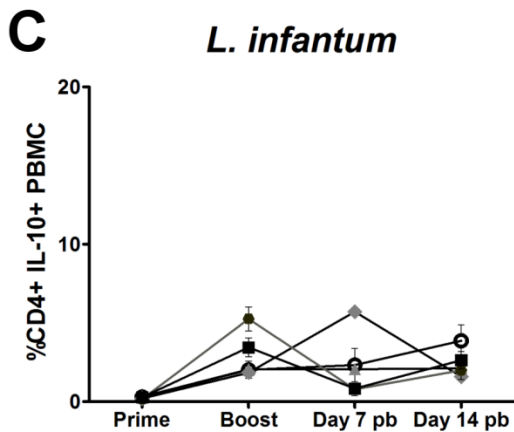
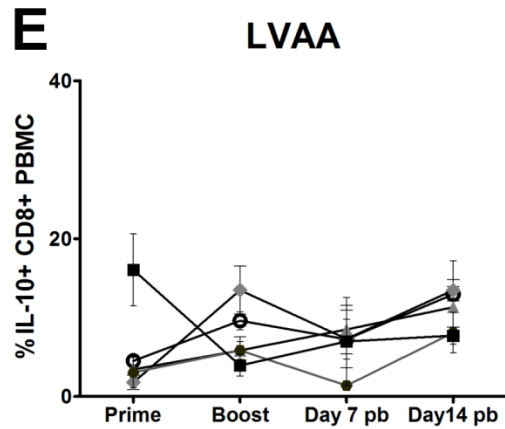
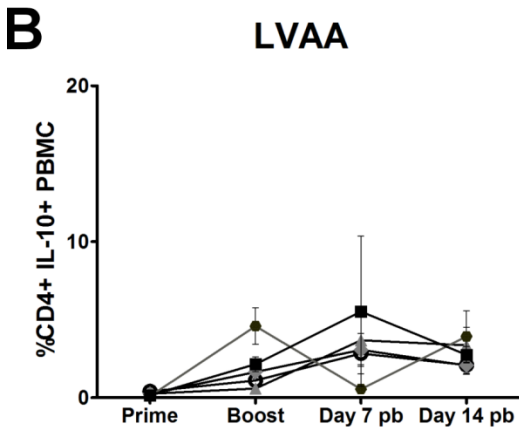
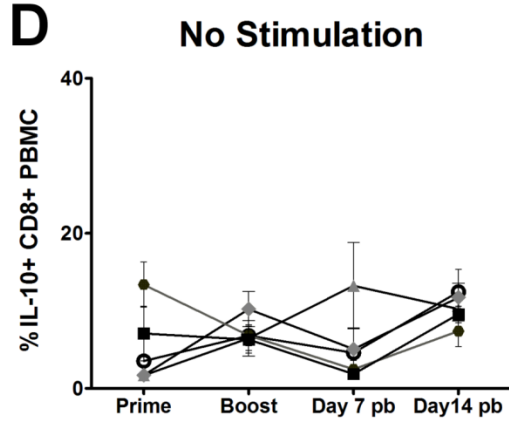
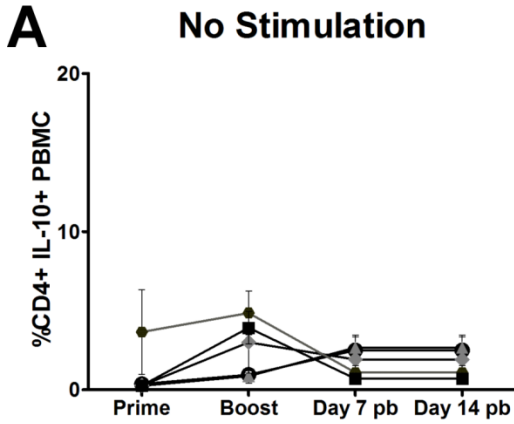
intra-cellular staining of CD4⁺ T cells for IFN γ (Figure 4.2E, F). This increase was observed after both stimulation with LVAA antigen and stimulation with whole f-t *L.i* (Figure 4.2E, F). At day 14 post-boost, IFN γ production was also significantly elevated in the Protein:Protein group (Figure 4.2E, F). ELISpot analysis for IFN γ production demonstrated minimal changes in the no stimulation group compared to some intracellular IFN- γ production and cellular proliferation in CD4⁺ T cells. This suggests that while CD4⁺ T cell proliferation and intracellular IFN γ production were increased in the no-stimulation groups at boost to 14 days post-boost, actual secretion of IFN γ was minimal in the absence of antigen stimulation. Discrepancies between results obtained by intracellular staining and ELISpot could be attributed to technical differences (incubation times) or functional differences (e.g., intracellular processing or secretion of IFN γ). The ELISpot method measures the accumulation of secreted cytokine over the entire incubation period, while intracellular staining determines how much intracellular IFN γ accumulated during a span of 6 hours after brefeldin A treatment following 7 days of incubation. Regardless, dogs vaccinated with the Ad:Protein and Ad:Pox had superior Th1-oriented IFN γ production in response to antigen than other groups and Ad:Pox was more consistent and optimal to the Ad:Protein group, although not statistically different.

Production of IFN γ by CD8⁺ T cells after vaccination followed a trend similar to, although not as pronounced as that of CD4⁺ T cells (Figure 4.3). Stimulation of PBMC with LVAA at 14 days post-boost induced a significant elevation of intracellular IFN γ in the Ad:Protein ($p < 0.05$) and Ad:Pox ($p < 0.001$) group (Figure 4.3B). IFN γ production after stimulation with whole f-t *L.i* was significantly elevated only within the Ad:Pox group at day

Figure 4.4. Vaccination with LVAA vaccine preparations resulted in limited CD4+ and CD8+ T cell production of IL-10. PBMC were collected from naïve (day 0) and previously primed (Day21; Boost), or previously boosted (Day7 pb, Day14 pb) laboratory dogs and stimulated with media (no stimulation, top row), 10 µg/ml of LVAA vaccine antigen (LVAA, middle row), or 10 µg/ml whole f-t *L. infantum* antigen (*L. infantum*, bottom row) for 7 days. Proliferation was measured via 24 hour uptake of EdU. **A-C**) CD4+ PBMC intracellular IL-10 7 days after no stimulation (**A**), LVAA (**B**), and f-t *L.i.* (**C**). **D-F**) CD8+ PBMC intracellular IL-10 7 days after no stimulation (**D**), LVAA (**E**), and f-t *L.i.* (**F**). Data was analyzed with GraphPad Prism 5 via 2-way ANOVA of all treatments over repeated time points with Bonferroni post-test. All graphs are shown as population data with error bars as SEM.

CD4+ PBMC

CD8+ PBMC



- Adenovirus: Pox
- ◆ Adenovirus: Protein
- ◇ DNA: Protein
- ★ Protein: Protein
- ⊖ Control

14 post-boost compared to the control group (Figure 4.3C). A spike in IFN γ intracellular production in the no stimulation group observed in CD4+ cells and in PBMC as a whole, was present, but was not statistically significant in the CD8+ T cell population. As a whole, vaccination of dogs with Ad:Pox LVAA results in significant elevation of intracellular IFN γ in CD4+ and CD8+ T cells and a significant increase in the secretion of IFN γ from PBMC in response to LVAA and whole f-t *L.i.*

LVAA vaccination strategies do not skew toward IL-10 production after antigen re-stimulation

Vaccine responses skewed toward a Th2 or regulatory T cell response are characterized by increased levels of the cytokine IL-10 are associated with reduced Th1 cell-mediated immune responses, necessary for protection against intracellular pathogens such as *L. infantum* [32, 34]. Furthermore, elevated levels of IL-10 early in infection with *Leishmania spp.* has been associated with increased parasite burdens and increased severity of infection [35]. To determine if IL-10 was induced in response to vaccine and f-t *L.i.*, we stimulated PBMC from vaccinated and control dogs ex vivo with 10 μ g/ml of LVAA and 10 μ g/ml f-t *L.i.* for 7 days. We evaluated intracellular IL-10 by flow cytometry in CD4+ and CD8+ populations (Figure 4.4). There were no significant changes in CD4+ IL-10 production in response to LVAA or whole f-t *L.i.* in any group (Figure 4.4a, b, c). Similarly, there were no significant elevations in IL-10 from CD8+ T cells compared to control (Figure 4.4D, E, F). The DNA:Protein group was significantly elevated in IL-10 production compared to the Ad:Protein and Ad:Pox groups at day 28 (Figure 4.4F). None of the vaccine preparations induced pronounced elevations in intracellular IL-10.

In conjunction with a minimal induction of IL-10, the significant production of IFN γ and CD4⁺ T cell proliferation indicates optimal immunogenicity toward a Th1 cell mediated response in response to Ad:Protein and Ad:Pox LVAA vaccination, with the most pronounced responses observed within the Ad:Pox group.

DISCUSSION

The development of vaccines against some of history's greatest plagues of animals and humans have saved countless lives and resulted in the eradication or near eradication of some diseases from the planet, like smallpox and rinderpest. However, chronic intracellular infections with pathogens like *Mycobacterium tuberculosis*, *Trypanosoma cruzi*, and *Leishmania* spp. have proven significantly more difficult to prevent due to the immune escape mechanisms of the pathogen, the complex transmission cycles of zoonotic pathogens, and the requirement for enhanced cell-mediated and innate immunity rather than a protective antibody response [1, 16, 36]. Historically, active infection with a small number of *Leishmania* spp. parasites, Leishmanization, has resulted in reasonable protection against cutaneous leishmaniasis likely due to the persistence of a small number of parasites at the lesion site, and a continued release of antigen [12]. This approach is still disfiguring and quality control is difficult because active lesions can arise at much later times [15]. The use of the complex fucose-mannose ligand of *L. donovani* with saponin adjuvant (Leishmune®) has been moderately effective in reducing clinical disease in dogs with an approximate reduction in clinical disease by 60-75% after 2 years [19]. However, while reports indicate that Leishmune may inhibit transmission out to 11 months [37], it is less clear if these dogs

remain parasitemic and capable of infecting sandflies under real-world conditions long-term. The duration of protection with this approach is also short, and there is a high percentage of adverse events post-vaccination with Leishmune® [20]. In endemic areas, it is unclear whether individual animals receiving the vaccine are truly naïve, and in fact in many regions it is highly unlikely that vaccinees have not had previous exposure [31, 38, 39]. Prior exposure presents a special challenge, as vaccination may serve more as an immunotherapeutic than a prophylactic vaccination. Another difficulty may be that any vaccine must overcome an immune response previously molded by exposure to parasites and sandfly saliva. An optimal vaccine candidate must mimic an asymptomatic infection in which the infection is cleared. In fact, it must assist clearance in infected, asymptomatic dogs. In addition, the vaccination must result in memory responses capable of effectively clearing subsequent exposures without establishment of chronic infection.

Second-generation vaccines utilizing specific combinations of immunogens, such as L110f, have demonstrated promising results in mice, resulting in cell-mediated immunogenicity in BALB/c and C57/B6 mice with protection, dependent upon experimental conditions [24, 25, 40, 41]. Gene-deletion live parasite vaccination strategies have recently emerged as a potential avenue to generate an immune response to live infection [17, 18, 42]. Centrin-deleted *Leishmania donovani*, which can replicate as promastigotes in culture, but are replication-deficient as amastigotes in the mammalian host, has emerged recently as a vaccine candidate [18, 41]. This replication-deficient *L. donovani* was protective in BALB/c mice and Syrian golden hamsters 10 weeks post-challenge [18]. The translation of second generation vaccines from rodent models into dogs or humans has proven exceedingly difficult. L110f had a limited to moderate efficacy in an endemic region of Italy, without a

significant delay in clinical signs compared to controls [27]. Centrin-deleted, live attenuated vaccines are similarly immunogenic in dogs, but no challenge studies have been published to date [42]. In this study, we have demonstrated the immunogenicity of LVAA in the induction of a Th1-focused CD4+ and CD8+ memory response. This response is similar to previous studies into recombinant protein sub-unit vaccines in mice and in dogs. LVAA demonstrated a significant increase in cellular proliferation and IFN γ production in both CD4+ and CD8+ T cells with a minimal increase in intracellular IL-10. In numerous studies, these immunologic parameters are defined correlates of immunity against VL-causing species of *Leishmania*, and while not perfect, the efficacy of LVAA in inducing this type of immune signature after vaccination in the target species demonstrates significant potential.

There was no increase in nitric oxide indirectly measured by the presence of organic nitrites via the Griess assay (data not shown, Supplemental Figure 1). In mice, iNOS2 is highly expressed with a large generation of nitric oxide in response to elevated IFN γ . In dogs, elevations of nitrite are very subtle, likely due to species differences, similar to murine and human macrophage phenotypic differences, which have been controversially discussed over the last decade [43]. Syrian golden hamsters have impaired activation of iNOS as well, due to reduced binding of nuclear factor IL-6 (NF IL-6) to the iNOS promoter compared to mice [44]. It is possible that canines and humans have similar alterations compared to mice, or that aerobic culture conditions are not permissive to iNOS production in humans and dogs, but are in murine macrophages, as suggested separately by Bogdan and Nathan [45, 46].

Vaccine preparation also has a large influence on the efficacy and safety of vaccination. Within this study we analyzed multiple modalities of immune activation by LVAA including protein with TLR4 agonist, plasmid containing LVAA-coding DNA,

Adenovirus-vector LVAA, and Canary pox-vector LVAA. DNA vaccines have shown potential. In theory, these vaccines can induce resident tissues, usually skeletal myocytes and antigen presenting cells, to present antigen on both MHC class I and II [47]. However, plasmid uptake can be highly variable, and often these vaccines have poor immunogenicity compared to traditional protein vaccines [47, 48]. DNA:Protein LVAA vaccine showed some indication of priming of CD8+ T cells, possibly through presentation on MHC class I, as compared to CD4+ responses to this same vaccine preparation. However, plasmid incorporation may have been inconsistent, as 3 dogs (50% of the group) demonstrated significant levels of proliferation (39%, 51.7%, and 14.4% of CD4+ T cells; 46%, 46.3%, and 9.72% of CD8+ T cells) and IFN γ production (21.6%, 27.3%, and 9.72% of CD4+ T cells; all groups CD8+ T cells >20%), and 3 dogs (50% of the group) had almost no proliferative response (<5% in both CD4+ and CD8+ T cells) and minimal CD4+ T-cell intracellular IFN γ (<10% in CD4+ T cells). It may be possible to improve this vaccine preparation although the viral-vectored and protein vaccine preparations were significantly more immunogenic.

For some of the analyses LVAA protein used either in heterologous prime-boost experiments or in adenovirus only form performed better than using only LVAA protein formulated with the GLA adjuvant. However, in other cases such as IFN γ ELISpot assays, Protein:Protein appeared to require boosting, but ultimately resulted in equivalent numbers of cells producing IFN γ as the heterologous prime-boost groups. Previous studies of second-generation candidates such as L111f/L110f and KSAC have utilized fusion protein plus TLR agonist for vaccination demonstrating protection in mice and hamsters [23-26, 41]. The subunit polyprotein antigen L111f, when combined with the TLR4 agonist in stable emulsion

MPL-SE, has provided moderate to limited immunotherapeutic cure in dogs [28], and the related subunit polyprotein antigen MML gave moderate to limited protection [27]. The results of our study are consistent with the previous reports for L111f and MML.

LVAA protein used directly with the GLA adjuvant was less efficient at priming a Th1 response during this experiment compared to other preparations. Previous studies of second generation candidates such as L110f have utilized fusion protein plus TLR agonist for vaccination demonstrating some protection in mice and hamsters [23-26, 41]. However, subunit polyprotein vaccines with TLR4 agonists have had limited protection and immunotherapy in dogs [27]. The results of this study are consistent with these previous subunit vaccine reports.

Viral vector vaccine preparations using replication-deficient adenovirus vectors are highly immunogenic, as the adenovirus capsid and genome illicit strong responses to the expressed antigen [49-51]. Adenovirus preparations were only used as priming vaccinations in this study due to the risk of immune focusing toward dominant vector-derived antigens and not LVAA polyprotein. Adenoviral-vector LVAA priming with protein or canary pox-vector LVAA boost were significantly the most immunogenic vaccine preparations for both CD4+ and CD8+ T cells and for whole PBMC secretion of IFN γ . This demonstrates that adenoviral-vectored vaccines in this study provided the most effective priming vaccination. Canarypox virus vectors for vaccination are unique and have the advantage of being replication deficient, of having very large vectoral capacity, and engage the innate immune system, including Type I IFN induction, activation of inflammasome pathways, and induction of NF κ B signaling [52]. However, it is remarkable how little is known about how canarypox viruses interact with the innate immune system [52]. Canarypox-vector LVAA

performed the best over other groups as a boost vaccination to Adenovirus-vector LVAA primary vaccination. We did observe prolonged proliferation of CD4⁺ T cells in non-stimulated groups up to 14 days post-vaccination (Figure 4.1, 2) with this treatment. With this non-specific proliferation subtracted, the Ad:Protein platform generated the most consistent responses of cellular proliferation and IFN γ . It is unlikely that the non-specific proliferative response of the Ad:Pox group was due to a comorbid disease in these dogs as it occurred in all dogs of one experimental group, housed in three different kennels, and in no animals of other groups. It is also unlikely that this finding could be due to experimental error because both proliferative and IFN γ responses were elevated in all animals of this group across two time points and in no other experimental group (Figure 4.1, 2). It is possible that the induction of a pronounced Th1 response may have been due to the persistence of LVAA secretion, even in the absence of viral vector replication.

This study demonstrates the immunogenicity of LVAA antigen with an Adenoviral-vector LVAA prime and LVAA protein/GLA or canary pox-vector LVAA boost. The most pronounced overall Th1 response was observed within the Ad:Pox group and the greatest antigen-specific Th1 response in the Ad:Protein group, as demonstrated by a proliferative response and IFN γ production in response to LVAA antigen and whole f-t *L.i.* in both CD4⁺ and CD8⁺ lymphocytes. Our data, generated using several different formulations, support LVAA as a vaccine antigen that appears suitable for the prevention of canine leishmaniasis. Further studies to evaluate the efficacy of the Ad:Pox and the Ad:Protein LVAA protocols under challenge conditions in dogs are warranted.

ACKNOWLEDGEMENTS

We would like to thank the efforts and cooperation of the Iowa State University Department of Laboratory Animal Resources, for their technical expertise and assistance. We would like to specifically thank Dr. Kathleen Mullin and Dr. Giuseppe Dell'anna for their additional expertise and assistance with this study.

REFERENCES

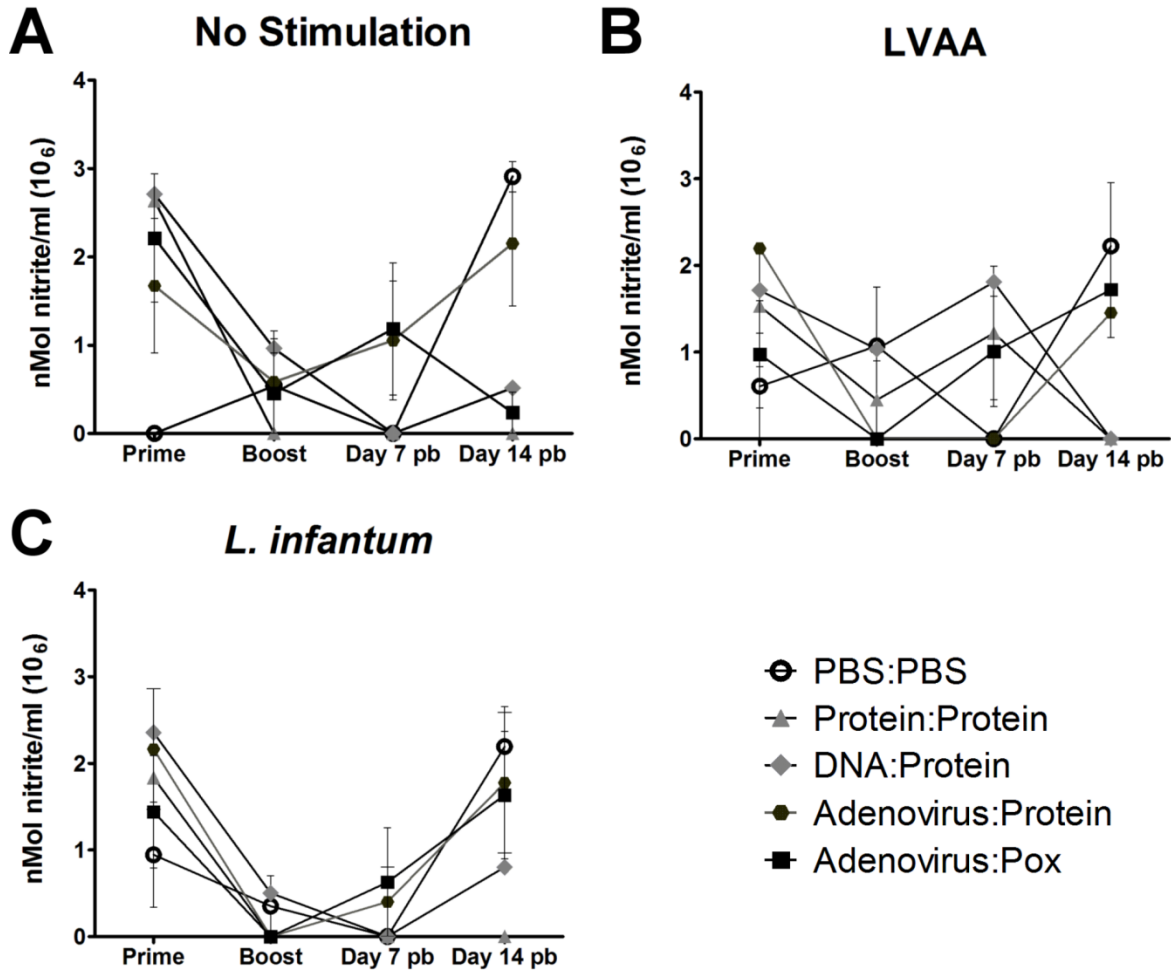
1. **Esch, K.J. and C.A. Petersen**, *Transmission and epidemiology of zoonotic protozoal diseases of companion animals*. Clin Microbiol Rev, 2013. **26**(1): p. 58-85.
2. **Esch, K.J., et al.**, *Preventing zoonotic canine leishmaniasis in northeastern Brazil: pet attachment and adoption of community Leishmania prevention*. Am J Trop Med Hyg, 2012. **87**(5): p. 822-31.
3. **Solano-Gallego, L., et al.**, *Directions for the diagnosis, clinical staging, treatment and prevention of canine leishmaniosis*. Vet Parasitol, 2009. **165**(1-2): p. 1-18.
4. **Scott, P., et al.**, *Immunoregulation of cutaneous leishmaniasis. T cell lines that transfer protective immunity or exacerbation belong to different T helper subsets and respond to distinct parasite antigens*. J Exp Med, 1988. **168**(5): p. 1675-84.
5. **Skeiky, Y.A., et al.**, *A recombinant Leishmania antigen that stimulates human peripheral blood mononuclear cells to express a Th1-type cytokine profile and to produce interleukin 12*. J Exp Med, 1995. **181**(4): p. 1527-37.
6. **Herwaldt, B.L. and J.D. Berman**, *Recommendations for treating leishmaniasis with sodium stibogluconate (Pentostam) and review of pertinent clinical studies*. Am J Trop Med Hyg, 1992. **46**(3): p. 296-306.
7. **Olliaro, P.L., et al.**, *Treatment options for visceral leishmaniasis: a systematic review of clinical studies done in India, 1980-2004*. Lancet Infect Dis, 2005. **5**(12): p. 763-74.
8. **Hay, R.J.**, *Liposomal amphotericin B, AmBisome*. J Infect, 1994. **28 Suppl 1**: p. 35-43.

9. **Bose, A.N., T.N. Ghosh, and et al.,** *On the toxicity of some organic antimonial drugs used for the treatment of kala-azar.* Ind Med Gaz, 1946. **81**: p. 13-6.
10. **Meyerhoff, A.,** *U.S. Food and Drug Administration approval of AmBisome (liposomal amphotericin B) for treatment of visceral leishmaniasis.* Clin Infect Dis, 1999. **28**(1): p. 42-8; discussion 49-51.
11. **Torres, M., et al.,** *Long term follow-up of dogs diagnosed with leishmaniosis (clinical stage II) and treated with meglumine antimoniate and allopurinol.* Vet J, 2011. **188**(3): p. 346-51.
12. **Khamesipour, A., et al.,** *Leishmanization: use of an old method for evaluation of candidate vaccines against leishmaniasis.* Vaccine, 2005. **23**(28): p. 3642-8.
13. **Nadim, A., et al.,** *Effectiveness of leishmanization in the control of cutaneous leishmaniasis.* Bull Soc Pathol Exot Filiales, 1983. **76**(4): p. 377-83.
14. **Hosseini, S.M., G.R. Hatam, and S. Ardehali,** *Characterization of Leishmania isolated from unhealed lesions caused by leishmanization.* East Mediterr Health J, 2005. **11**(1-2): p. 240-3.
15. **Khamesipour, A., et al.,** *Treatment of cutaneous lesion of 20 years' duration caused by leishmanization.* Indian J Dermatol, 2012. **57**(2): p. 123-5.
16. **Duthie, M.S., et al.,** *The development and clinical evaluation of second-generation leishmaniasis vaccines.* Vaccine, 2012. **30**(2): p. 134-41.
17. **Selvapandiyam, A., et al.,** *Immunity to visceral leishmaniasis using genetically defined live-attenuated parasites.* J Trop Med, 2012. **2012**: p. 631460.
18. **Selvapandiyam, A., et al.,** *Intracellular replication-deficient Leishmania donovani induces long lasting protective immunity against visceral leishmaniasis.* J Immunol, 2009. **183**(3): p. 1813-20.
19. **da Silva, V.O., et al.,** *A phase III trial of efficacy of the FML-vaccine against canine kala-azar in an endemic area of Brazil (Sao Goncalo do Amaranto, RN).* Vaccine, 2000. **19**(9-10): p. 1082-92.
20. **Parra, L.E., et al.,** *Safety trial using the Leishmune vaccine against canine visceral leishmaniasis in Brazil.* Vaccine, 2007. **25**(12): p. 2180-6.
21. **Zanin, F.H., et al.,** *Evaluation of immune responses and protection induced by A2 and nucleoside hydrolase (NH) DNA vaccines against Leishmania chagasi and*

- Leishmania amazonensis* experimental infections. *Microbes Infect*, 2007. **9**(9): p. 1070-7.
22. **Fernandes, A.P., et al.**, *Protective immunity against challenge with Leishmania (Leishmania) chagasi in beagle dogs vaccinated with recombinant A2 protein*. *Vaccine*, 2008. **26**(46): p. 5888-95.
 23. **Goto, Y., et al.**, *KSAC, the first defined polyprotein vaccine candidate for visceral leishmaniasis*. *Clin Vaccine Immunol*, 2011. **18**(7): p. 1118-24.
 24. **Coler, R.N., et al.**, *Leish-111f, a recombinant polyprotein vaccine that protects against visceral Leishmaniasis by elicitation of CD4+ T cells*. *Infect Immun*, 2007. **75**(9): p. 4648-54.
 25. **Peters, N.C., et al.**, *Evaluation of recombinant Leishmania polyprotein plus glucopyranosyl lipid A stable emulsion vaccines against sand fly-transmitted Leishmania major in C57BL/6 mice*. *J Immunol*, 2012. **189**(10): p. 4832-41.
 26. **Gomes, R., et al.**, *KSAC, a defined Leishmania antigen, plus adjuvant protects against the virulence of L. major transmitted by its natural vector Phlebotomus duboscqi*. *PLoS Negl Trop Dis*, 2012. **6**(4): p. e1610.
 27. **Gradoni, L., et al.**, *Failure of a multi-subunit recombinant leishmanial vaccine (MML) to protect dogs from Leishmania infantum infection and to prevent disease progression in infected animals*. *Vaccine*, 2005. **23**(45): p. 5245-51.
 28. **Trigo, J., et al.**, *Treatment of canine visceral leishmaniasis by the vaccine Leish-111f+MPL-SE*. *Vaccine*, 2010. **28**(19): p. 3333-40.
 29. **Peters, N.C., et al.**, *In vivo imaging reveals an essential role for neutrophils in leishmaniasis transmitted by sand flies*. *Science*, 2008. **321**(5891): p. 970-4.
 30. **Boggiatto, P.M., et al.**, *Altered dendritic cell phenotype in response to Leishmania amazonensis amastigote infection is mediated by MAP kinase, ERK*. *Am J Pathol*, 2009. **174**(5): p. 1818-26.
 31. **Boggiatto, P.M., et al.**, *Transplacental transmission of Leishmania infantum as a means for continued disease incidence in North America*. *PLoS Negl Trop Dis*, 2011. **5**(4): p. e1019.
 32. **Boggiatto, P.M., et al.**, *Immunologic indicators of clinical progression during canine Leishmania infantum infection*. *Clin Vaccine Immunol*, 2010. **17**(2): p. 267-73.

33. **Yang, T.C., et al.**, *The CD8+ T cell population elicited by recombinant adenovirus displays a novel partially exhausted phenotype associated with prolonged antigen presentation that nonetheless provides long-term immunity.* J Immunol, 2006. **176**(1): p. 200-10.
34. **Nylen, S., et al.**, *Splenic accumulation of IL-10 mRNA in T cells distinct from CD4+CD25+ (Foxp3) regulatory T cells in human visceral leishmaniasis.* J Exp Med, 2007. **204**(4): p. 805-17.
35. **Nylen, S. and D. Sacks**, *Interleukin-10 and the pathogenesis of human visceral leishmaniasis.* Trends Immunol, 2007. **28**(9): p. 378-84.
36. **Checkley, A.M. and H. McShane**, *Tuberculosis vaccines: progress and challenges.* Trends Pharmacol Sci, 2011. **32**(10): p. 601-6.
37. **Nogueira, F.S., et al.**, *Leishmune vaccine blocks the transmission of canine visceral leishmaniasis: absence of Leishmania parasites in blood, skin and lymph nodes of vaccinated exposed dogs.* Vaccine, 2005. **23**(40): p. 4805-10.
38. **da Silva, S.M., et al.**, *First report of vertical transmission of Leishmania (Leishmania) infantum in a naturally infected bitch from Brazil.* Vet Parasitol, 2009. **166**(1-2): p. 159-62.
39. **Pangrazio, K.K., et al.**, *Tissue distribution of Leishmania chagasi and lesions in transplacentally infected fetuses from symptomatic and asymptomatic naturally infected bitches.* Vet Parasitol, 2009. **165**(3-4): p. 327-31.
40. **Skeiky, Y.A., et al.**, *Protective efficacy of a tandemly linked, multi-subunit recombinant leishmanial vaccine (Leish-111f) formulated in MPL adjuvant.* Vaccine, 2002. **20**(27-28): p. 3292-303.
41. **Bertholet, S., et al.**, *Optimized subunit vaccine protects against experimental leishmaniasis.* Vaccine, 2009. **27**(50): p. 7036-45.
42. **Fiuza, J.A., et al.**, *Induction of immunogenicity by live attenuated Leishmania donovani centrin deleted parasites in dogs.* Vaccine, 2013.
43. **Murray, P.J. and T.A. Wynn**, *Obstacles and opportunities for understanding macrophage polarization.* J Leukoc Biol, 2012. **89**(4): p. 557-63.
44. **Saldarriaga, O.A., et al.**, *Identification of hamster inducible nitric oxide synthase (iNOS) promoter sequences that influence basal and inducible iNOS expression.* J Leukoc Biol, 2012. **92**(1): p. 205-18.

45. **Bogdan, C.**, *Nitric oxide and the immune response*. Nat Immunol, 2001. **2**(10): p. 907-16.
46. **Nathan, C.**, *Role of iNOS in human host defense*. Science, 2006. **312**(5782): p. 1874-5; author reply 1874-5.
47. **Liu, M.A.**, *DNA vaccines: an historical perspective and view to the future*. Immunol Rev, 2011. **239**(1): p. 62-84.
48. **Xu, L. and T. Anchordoquy**, *Drug delivery trends in clinical trials and translational medicine: challenges and opportunities in the delivery of nucleic acid-based therapeutics*. J Pharm Sci, 2011. **100**(1): p. 38-52.
49. **Appledorn, D.M., et al.**, *Complex interactions with several arms of the complement system dictate innate and humoral immunity to adenoviral vectors*. Gene Ther, 2008. **15**(24): p. 1606-17.
50. **Appledorn, D.M., et al.**, *Adenovirus vector-induced innate inflammatory mediators, MAPK signaling, as well as adaptive immune responses are dependent upon both TLR2 and TLR9 in vivo*. J Immunol, 2008. **181**(3): p. 2134-44.
51. **Barlan, A.U., et al.**, *Adenovirus membrane penetration activates the NLRP3 inflammasome*. J Virol, 2011. **85**(1): p. 146-55.
52. **Lousberg, E.L., et al.**, *Innate immune recognition of poxviral vaccine vectors*. Expert Rev Vaccines, 2011. **10**(10): p. 1435-49.



Supplemental Figure 1. Vaccination with LVAA vaccine preparations resulted in limited PBMC nitrite production ex vivo. PBMC were collected from naïve (day 0) and previously primed (Day21; Boost), or previously boosted (Day7 pb, Day14 pb) laboratory dogs and stimulated with media (no stimulation, **A**), 10 $\mu\text{g}/\text{ml}$ of LVAA vaccine antigen (LVAA, **B**), or 10 $\mu\text{g}/\text{ml}$ whole f-t *L. infantum* antigen (*L. infantum*, **C**) for 24 hours. Cell supernatants were harvested for the Greiss assay indirect measure of iNOS activity. **A-C** nMol of organic nitrite (10^6) in response to no stimulation (**A**), LVAA (**B**), and f-t *L.i.* (**C**). Data was analyzed with GraphPad Prism 5 via 2-way ANOVA of all treatments over repeated time points with Bonferroni post-test. All graphs are shown as population data with error bars as SEM.

CHAPTER 5

GENERAL CONCLUSIONS

SUMMARY

The work presented in this thesis contains novel characterizations of the immune response to and immunopathology of visceral leishmaniasis. Within the first section is the first characterization of functional pan-T cell exhaustion during naturally-occurring visceral leishmaniasis, mediated by co-inhibitory receptor Programmed Death 1 (PD-1) and its interaction with ligand B7.H1 on antigen presenting cells. This data suggests that during chronic infection with *Leishmania infantum* both CD4+ and CD8+ T cells develop immune exhaustion, characterized by impairment of proliferative potential and IFN γ production from CD4+ and CD8+ T cells, and elevation in IL-10 production from CD4+ T cells. All animals categorized as symptomatic had CD4+ and CD8+ T cell populations with characteristics of functional exhaustion. Within the VL asymptomatic population nearly one half of animals had phenotypically exhausted CD8+ T cell populations. Similarly, nearly one half of the CD4+ T cell population demonstrated impaired IFN γ production, but still proliferated in response to *L. infantum* antigen. These functional changes were associated with a significant elevation in co-inhibitory receptor PD-1. Pan-T cell exhaustion was also associated with phenotypic alterations in monocyte-derived macrophages, with impaired production of superoxide and decreased parasite killing, recovered by blockade of PD-1/B7.H1.

Blockage of the PD-1 ligand B7.H1 on antigen presenting cells recovered CD4+ and CD8+ T cell proliferative capacity. A partial recovery of IFN γ production was achieved after

B7.H1 blockade within the CD4⁺ T cell population. However, within the CD8⁺ T cell population, only IL-10 blockage resulted in a slight but significant recovery of IFN γ production. Stimulation with *L. infantum* antigen did not result in increased apoptosis in either CD4⁺ or CD8⁺ T cell populations, suggesting that the process of T cell exhaustion leads to the survival of a non-responsive, antigen-specific T cell population, whose effector function is partially recoverable by blockade of PD-1/B7.H1 or IL-10.

Immunopathology during infection with multiple different *Leishmania* spp. is well-recognized [1, 2]. To date, the understanding of VL immunopathology has been limited to over-expression of immuno-inhibitory cytokines (like IL-10), the suppressive functions of regulatory T cells, and parasite-derived mechanisms of immune evasion [1, 3-5]. While all of these contributions are unambiguously integral to VL pathogenesis and immunity, therapeutic or preventive approaches targeting these discoveries have only been moderately successful [6-8]. This indicated additional, previously unrecognized, immunopathology during VL. The data presented in the first section of this thesis contributes additional novel components to pathogenesis of symptomatic VL. Targeting PD-1 and IL-10 blockade singly or in combination in conjunction with pharmacologic intervention, may improve long-term outcomes and immunity. In addition, the research presented here may lead to the evaluation and/or identification of additional mechanisms of co-inhibition necessary for the precipitation of symptomatic VL.

Immunopathology during symptomatic VL is associated with excessive production of IgG and subsequent hypergammaglobulinemia [9]. This serum chemistry abnormality is present during symptomatic VL in both dogs and humans, and thought to be responsible for the formation of rheumatoid factors and the development of immune complex-mediated

glomerulonephritis [10-12]. Previous reports of VL-associated glomerulonephritis provided conflicting accounts of the pathogenesis and classification of the glomerular lesions and the components of protein deposits within the glomerular basement membrane [13-15]. The study presented in the second section of this thesis utilized routine histologic, ultrastructural, and immunohistochemical analyses to classify VL-associated glomerulonephritis as a Type I membranoproliferative glomerulonephritis (MPGN) with segmental subendothelial and mesangial deposits composed of *L. infantum* antigen, IgG, and C3. In addition tubulointerstitial regions of the kidney contained moderate to severe lymphoplasmacytic and histiocytic inflammation with occasional intrahistiocytic *L. infantum* parasites.

Chronic renal disease is a major cause of morbidity and mortality in the world, and is the ninth leading cause of death in the United States [16, 17]. In addition, approximately \$33 billion USD in health care expenditures are directed toward the therapy of renal disease each year [17]. Glomerulopathy due to numerous different causes is a major cause of functional impairment of the kidney and subsequent end stage renal disease (ESRD). The response to accumulated protein and immune complexes in the glomerular basement membrane by three major cell types that construct and maintain the glomerular filtration apparatus (podocytes, mesangial cells, and glomerular capillary endothelial cells) is incompletely understood. Macroautophagy is a cellular processing mechanism necessary for the basal function of podocytes and mesangial cells [18, 19]. Pro-inflammatory cytokines IL-1 β and IL-18 are known to promote renal inflammation [20, 21]. However, the role of the NLRP3 inflammasome and the source of these pro-inflammatory cytokines is unknown. Using naturally-occurring canine VL as a model of Type I MPGN, we evaluated the presence of autophagosomes identified as “LC3 puncta” and of NLRP 3, a protein associated with the

NLRP3 inflammasome in glomerular cells from normal, asymptomatic, and symptomatic VL dogs. The level of autophagy and the amount of NLRP3 were both significantly elevated in both asymptomatic and symptomatic VL dogs compared to controls. Levels of both proteins were also significantly elevated in symptomatic VL compared to asymptomatic dogs. This was consistent in both formalin-fixed paraffin embedded and frozen cryosections. While it was impossible to elucidate causation from this retrospective cross-sectional study, this data strongly supports a role for macroautophagy and the NLRP3 inflammasome as either precipitating factors for or a response to immune-mediated glomerular disease.

Achieving effective prevention against VL will require the stimulation of cell-mediated immunity, including CD4⁺ T cell immunity, capable of parasite clearance prior to the initiation of established infection. In addition, since the exposure rate of patients within endemic regions is likely high, such a vaccine would also have to serve as an effective immunotherapeutic in previously exposed or asymptotically infected persons. The mechanisms of immunopathology characterized within the first two sections of this thesis may further complicate the achievement of effective immunity. At the present, correlates of protective immunity for prevention of VL are thought to be robust CD4⁺ and CD8⁺ memory T cell proliferation and production of IFN γ in response to *L. infantum* antigen [8].

In the third section of this thesis we evaluated the immunogenicity of a novel proprietary polypeptide vaccine against canine leishmaniasis (CanL), *Leishmania* vaccine antigen A (LVAA), in multiple platforms. We discovered that LVAA has exceptional potential as a vaccine candidate for CanL, resulting in significant proliferation and production of IFN γ in both CD4⁺ and CD8⁺ T cell populations in the Ad:Pox group compared to PBMC responses from other groups. LVAA vaccination did not induce a

significant increase in IL-10 from PBMC of dogs in any group. This study demonstrates a pronounced effector memory response to LVAA vaccination, and further studies may elucidate the potential efficacy of LVAA under field conditions.

DISCUSSION

Immunopathology of visceral leishmaniasis

Immunity against *Leishmania infantum* requires a robust Th1 response, including clonal expansion and proliferation of CD4⁺ T helper cells and the production of pro-inflammatory cytokine IFN γ . To achieve such a response, memory T cell populations must be present and responsive, dendritic cells and other antigen presenting cells must process and present antigen to these T cells, and infected macrophages in turn, must be stimulated to generate RNI and ROI capable of killing intracellular parasites. Parasite-derived mechanisms of host evasion are common. Two host evasion strategies are parasite surface expression of phosphatidylserine using so-called apoptotic mimicry to target alternatively activated macrophages, and the induction of phagocytosis by neutrophils for subsequent clearance by alternatively activated resident macrophages in a “trojan horse”-like manner [22][23]. Another is the alteration of dendritic cell phenotype via ERK 1/2 signaling and subsequent impairment of dendritic cell IL-12 production [24]. Effective preventive vaccination must be able to overcome these immune evasion strategies. As infection progresses, a sterile cure with effective long-term immunity is even more difficult to achieve. Previously initiated immune dysregulation including potential Th2 skewing, the preferential infection of alternatively activated macrophages, and pan-T cell exhaustion during asymptomatic and symptomatic infection that is described in the first section of this thesis become exceedingly

difficult to overcome as parasite numbers increase and disease progresses to a clinical state. Therefore, the goal of reaching a sterile cure or a truly preventive vaccine for VL by simply initiating a robust T helper cell response may be very difficult without additionally targeting immune evasion strategies of the parasite and host immunopathology.

Immune exhaustion has been previously characterized during various different chronic infections as a step-wise loss of function of T cells in response to specific antigen. Based on the characterization of exhaustion presented in this thesis, it is apparent that pan-T cell exhaustion is present during naturally-occurring VL. CD4⁺ T cell exhaustion in VL seems to be correlated with the onset of symptomatic disease. However, within the CD8⁺ T cell population, exhaustion was common in the asymptomatic cohort as well. Our hypothesis from this data is that functional T cell exhaustion present during asymptomatic infection aids in the transition from asymptomatic infection to symptomatic VL. This could be either a host-derived immunopathology developed from the inability to control infection with *Leishmania infantum*, or induced by the parasite directly as a means of host evasion. Our data indicates substantial CD8⁺ T cell exhaustion prior to the onset of CD4⁺ T cell exhaustion during VL. This is an interesting finding, considering the primary source of antigen from the parasite would be through the phagolysosomal system and presented via MHC II to CD4⁺ T cells. It is possible that CD8⁺ T cells are more sensitive to exhaustion, as a mechanism of host protection to prevent direct cytotoxic T cell mediated autoimmunity. It is also feasible that while antigen is being presented continually to both populations, presentation to CD8⁺ T cells via MHC I occurs with inadequate co-stimulation or at a threshold of antigen presentation capable of inducing CD8⁺ T cell exhaustion. Dysregulation

of the immune system via pan-T cell exhaustion mediated by PD-1 is likely a major component of immune compromise leading to symptomatic VL.

Immune complex-mediated membranoproliferative MPGN

Excessive production of IgG and high levels of circulating *L. infantum* antigen are characteristic of symptomatic VL, and are predictive of the onset of symptomatic disease [9]. The formation of immune complexes of IgG and antigen were previously believed to be responsible for VL-associated renal disease. Studies evaluating this have had conflicting results [13, 14]. The second section of this thesis characterized VL-associated glomerulonephritis as a Type I membranoproliferative glomerulonephritis with segmental deposits of *L. infantum* antigen, C3, and IgG. These findings were associated with lymphoplasmacytic and histiocytic interstitial nephritis. Lesions consistent with these changes were identified in both asymptomatic and symptomatic animals. Previous reports have identified the importance of canonical autophagy in maintenance of the glomerular filtration apparatus [19]. Separate studies demonstrated that dendritic cells respond to immune complexes via the induction of non-canonical autophagy [25]. Our data clearly shows an increase in autophagy associated with infection with *Leishmania infantum*. Our hypothesis is that the response of glomerular podocytes and mesangial cells to immune complex deposition during glomerular pathologic insult occurs via a non-canonical autophagy pathway, separate from the basal organelle and protein recycling functions of the canonical pathway. It is also unknown whether immune complexes directly induce macroautophagy, or if the elevations seen in our study were the response of glomerular cells to ER stress. The formation of LC3+ compartments in an elevated number of glomerular

cells indicated an essential role for autophagy in either the direct response to immune complex deposition or as a mechanism to manage cellular stress within the glomerulus. Targeting of this pathway may be beneficial in either case to improve the clearance of deposited protein or limit the long term damage of immune complex deposition to the glomerular filtration apparatus.

NLRP3 is a protein associated with inflammasome formation in response to multiple different cellular stressors [26]. In response to inflammasome activation, the cleavage of Caspase 1 leads to the cleavage of pro-IL-1 β to form active IL-1 β [26]. IL-1 β and IL-18 are known to be associated with tubulointerstitial renal inflammation, although their role in glomerulonephritis is poorly understood [20, 27, 28]. The second chapter of this thesis demonstrated significant induction of NLRP3 within the glomerulus during VL-associated MPGN in both symptomatic and asymptomatic animals. Similarly to LC3, this induction could be either a direct result of immune complex deposition or a response to cellular stress. In either case, the significant induction NLRP3 likely contributes to the pro-inflammatory environment and further impairment of glomerular function.

Recent reports suggest that autophagy and inflammasome function may be linked as well. Harris et al. eloquently demonstrated the regulation of IL-1 β by autophagy at two levels, via degradation of pro-IL-1 β and of NLRP3 directly [29]. In another study, Shi et al. discovered the targeting of ubiquitinated inflammasomes for degradation within an autophagy pathway [30]. Immune complexes are known to stimulate collagen production and pro-inflammatory signals by mesangial cells through the engagement of Fc gamma receptor I and III [31]. Fc gamma receptor engagement generates ROS via NADPH oxidase targeting to LC3+ autophagosomes [32]. It is possible that Fc gamma receptor engagement induces

autophagy targeting of immune complexes, and that the induction of ROS primes NLRP3 for inflammasome activation. It is also possible that active NLRP3 is targeted for degradation within LC3+ autophagosomes. It is impossible however, to test these hypotheses in our current model or research as a part of this dissertation, but a plausible hypothesis could be made that immune complex deposition induces both NLRP3 inflammasome and LC3+ autophagy and that these contribute to glomerular inflammation and damage and preservation of the glomerular filtration apparatus respectively.

FUTURE STUDIES

Given the presence of pan-T cell exhaustion during VL, which was only partially responsive to blockade of PD-1 or IL-10, the logical pursuit of future studies is to determine additional co-inhibitory mechanisms responsible for the suppression of immune responses during exhaustion. The hypothesis could be made that additional known co-inhibitory receptors such as Cytotoxic T-lymphocyte antigen 4 (CTLA-4), T-cell immunoglobulin domain and mucin domain 3 (TIM-3), or Lymphocyte-activation gene 3 (LAG-3) may also contribute to functional exhaustion in this cohort. This could be evaluated by continuing the current project with a series of blocking experiments *ex vivo* to determine the contributions of each, with the goal of targeted therapeutic recovery of T cell immunity. Other experiments to determine distinct signaling mechanisms responsible for the induction of exhaustion could also be performed *ex vivo*. A proposed study would be to negatively select T cells from symptomatic VL and vaccinated uninfected dogs, stimulate them with bead-bound CD3 and bead-bound B7.H1 Fc fusion protein, or CD3 alone, to evaluate TCR signaling in response to CD3 ligation in these respective populations. Targets would include signaling through PI₃K

and negative regulation of Akt through the inhibitory molecule PTEN. Additionally, these T cells could be further phenotyped to determine their resemblance to T regulatory cells with expression of CD25 and FoxP3. Our current study also demonstrates alterations in macrophage phenotype induced by interaction with exhausted T cells. The mechanisms of this alteration are unknown. Using an *in vitro* model to induce T cell exhaustion in negatively selected T cells populations via bead-bound CD3 and B7.H1, evaluation of macrophage function after co-incubation would be possible. With mitogenic or antigenic stimuli, macrophage function could be evaluated in direct co-culture or in transwell to determine the necessity of receptor-ligand and bystander interactions. Also, a further defined transcriptomic evaluation of these exhaustion-impacted macrophages would be possible, to compare to previously characterized macrophage phenotypes. The proposed studies would add significantly to the base of knowledge of the immunopathology of visceral leishmaniasis and of T cell exhaustion.

The second section of this thesis demonstrates the potential involvement of NLRP3 and LC3+ autophagy in immune complex-mediated MPGN. The data presented in this cross-sectional cohort is purely associational and not causative, and future studies would be directed toward a mechanistic understanding of these two processes in MPGN. First, further defining the specific cell types conducting autophagy and NLRP3 inflammasome formation is paramount to understanding the pathogenesis of MPGN and is currently unknown. The utilization of podocyte-specific markers such as podocin and nephrin and a combination of smooth muscle actin, alpha-5 integrin, and dectin for mesangial cells would be sufficient. In addition, planned experiments using laser capture microscopy to identify transcriptional alterations related to the NLRP3 inflammasome and canonical and non-canonical autophagy

pathways will further elucidate the specific role of these pathways in MPGN. Specific cellular markers could be integrated into the laser capture microscopic procedure, using immunofluorescence to identify cells for capture. Subsequent studies will require the utilization of genetically engineered mice and perhaps a transition to a traditional experimental model of immune complex-mediated MPGN. Utilization of existing podocyte-conditional LC3 $-/-$, Fc gamma receptor 1 $-/-$, Beclin 1 $-/-$, and NLRP3 $-/-$ mice with the evaluation of lesion severity and immune complex deposition within the GBM, and alterations in renal function between genetically modified mice and wild-type mice would further identify causation versus association, and the role of canonical versus non-canonical autophagy in the response to immune complex deposition.

As a whole the research presented within this thesis contributes significantly to knowledge of asymptomatic and symptomatic VL. In addition, this research provides new avenues for extensive experimental research, all of which could be targeted toward therapeutic applications. These include the enhancement of immunity for prevention of VL, the recovery of immunity after exhaustion, the promotion of immune complex clearance from the glomerular filtration apparatus, and the mitigation of glomerular inflammation to provide improved long term outcomes after therapy. These long-term goals and research endeavors would contribute significantly to our knowledge of VL immunopathology and renal pathophysiology, and improve human and canine health.

REFERENCES

1. **Kaye, P. and P. Scott**, *Leishmaniasis: complexity at the host-pathogen interface*. Nat Rev Microbiol, 2011. **9**(8): p. 604-15.

2. **Kumar, R. and S. Nylen**, *Immunobiology of visceral leishmaniasis*. Front Immunol, 2012. **3**: p. 251.
3. **Kane, M.M. and D.M. Mosser**, *The role of IL-10 in promoting disease progression in leishmaniasis*. J Immunol, 2001. **166**(2): p. 1141-7.
4. **Nylen, S. and D. Sacks**, *Interleukin-10 and the pathogenesis of human visceral leishmaniasis*. Trends Immunol, 2007. **28**(9): p. 378-84.
5. **Belkaid, Y., et al.**, *CD4+CD25+ regulatory T cells control Leishmania major persistence and immunity*. Nature, 2002. **420**(6915): p. 502-7.
6. **Gautam, S., et al.**, *IL-10 neutralization promotes parasite clearance in splenic aspirate cells from patients with visceral leishmaniasis*. J Infect Dis, 2011. **204**(7): p. 1134-7.
7. **Kaye, P.M. and T. Aebischer**, *Visceral leishmaniasis: immunology and prospects for a vaccine*. Clin Microbiol Infect, 2011. **17**(10): p. 1462-70.
8. **Duthie, M.S., et al.**, *The development and clinical evaluation of second-generation leishmaniasis vaccines*. Vaccine, 2012. **30**(2): p. 134-41.
9. **Boggiatto, P.M., et al.**, *Immunologic indicators of clinical progression during canine Leishmania infantum infection*. Clin Vaccine Immunol, 2010. **17**(2): p. 267-73.
10. **Sakkas, L.I., et al.**, *Immunological features of visceral leishmaniasis may mimic systemic lupus erythematosus*. Clin Biochem, 2008. **41**(1-2): p. 65-8.
11. **Rocha, N.A., et al.**, *Visceral leishmaniasis in children: a cohort of 120 patients in a metropolitan city of Brazil*. Turk J Pediatr, 2011. **53**(2): p. 154-60.
12. **Lopez, R., et al.**, *Circulating immune complexes and renal function in canine leishmaniasis*. Zentralbl Veterinarmed B, 1996. **43**(8): p. 469-74.
13. **Poli, A., et al.**, *Renal involvement in canine leishmaniasis. A light-microscopic, immunohistochemical and electron-microscopic study*. Nephron, 1991. **57**(4): p. 444-52.
14. **Costa, F.A., et al.**, *T cells, adhesion molecules and modulation of apoptosis in visceral leishmaniasis glomerulonephritis*. BMC Infect Dis, 2010. **10**: p. 112.
15. **Dutra, M., et al.**, *Renal involvement in visceral leishmaniasis*. Am J Kidney Dis, 1985. **6**(1): p. 22-7.

16. *Prevalence of chronic kidney disease and associated risk factors--United States, 1999-2004.* MMWR Morb Mortal Wkly Rep, 2007. **56**(8): p. 161-5.
17. **CDC.** *Chronic Kidney Disease Initiative: Protecting Kidney Health.* 2012.
18. **Choi, A.M., S.W. Ryter, and B. Levine,** *Autophagy in human health and disease.* N Engl J Med, 2013. **368**(7): p. 651-62.
19. **Hartleben, B., et al.,** *Autophagy influences glomerular disease susceptibility and maintains podocyte homeostasis in aging mice.* J Clin Invest, 2010. **120**(4): p. 1084-96.
20. **Anders, H.J. and D.A. Muruve,** *The inflammasomes in kidney disease.* J Am Soc Nephrol, 2011. **22**(6): p. 1007-18.
21. **Lichtnekert, J., et al.,** *Anti-GBM glomerulonephritis involves IL-1 but is independent of NLRP3/ASC inflammasome-mediated activation of caspase-1.* PLoS One, 2011. **6**(10): p. e26778.
22. **Peters, N.C., et al.,** *In vivo imaging reveals an essential role for neutrophils in leishmaniasis transmitted by sand flies.* Science, 2008. **321**(5891): p. 970-4.
23. **Wanderley, J.L., et al.,** *Mimicry of apoptotic cells by exposing phosphatidylserine participates in the establishment of amastigotes of Leishmania (L) amazonensis in mammalian hosts.* J Immunol, 2006. **176**(3): p. 1834-9.
24. **Boggiatto, P.M., et al.,** *Altered dendritic cell phenotype in response to Leishmania amazonensis amastigote infection is mediated by MAP kinase, ERK.* Am J Pathol, 2009. **174**(5): p. 1818-26.
25. **Henault, J., et al.,** *Noncanonical autophagy is required for type I interferon secretion in response to DNA-immune complexes.* Immunity, 2012. **37**(6): p. 986-97.
26. **Strowig, T., et al.,** *Inflammasomes in health and disease.* Nature, 2012. **481**(7381): p. 278-86.
27. **Abais, J.M., et al.,** *NADPH Oxidase-Mediated Triggering of Inflammasome Activation in Mouse Podocytes and Glomeruli During Hyperhomocysteinemia.* Antioxid Redox Signal, 2012.
28. **Vilaysane, A., et al.,** *The NLRP3 inflammasome promotes renal inflammation and contributes to CKD.* J Am Soc Nephrol, 2010. **21**(10): p. 1732-44.

29. **Harris, J., et al.**, *Autophagy controls IL-1beta secretion by targeting pro-IL-1beta for degradation.* J Biol Chem, 2011. **286**(11): p. 9587-97.
30. **Shi, C.S., et al.**, *Activation of autophagy by inflammatory signals limits IL-1beta production by targeting ubiquitinated inflammasomes for destruction.* Nat Immunol, 2012. **13**(3): p. 255-63.
31. **Abdelsamie, S.A., et al.**, *Oxidized LDL immune complexes stimulate collagen IV production in mesangial cells via Fc gamma receptors I and III.* Clin Immunol, 2013. **139**(3): p. 258-66.
32. **Huang, J., et al.**, *Activation of antibacterial autophagy by NADPH oxidases.* Proc Natl Acad Sci U S A, 2009. **106**(15): p. 6226-31.

ACKNOWLEDGEMENTS

The work presented within this thesis is the embodiment of 4 years of research, training, and development. As such, the material in this thesis was directed not only by my original thoughts, but also by an innumerable multitude of ideas, suggestions, and pieces of knowledge from courses, journal clubs, meetings, seminars, and hallway conversations. I have been blessed with multiple outstanding mentors and friends, all of whom contributed significantly to this process.

I would first like to acknowledge my primary mentor, Dr. Christine Petersen. Over the last four years we have discussed research, planned experiments, revised manuscripts, written grants, traveled across the globe, and chatted about our families. She accepts her role as a mentor and has spent an enormous number of hours teaching me not only how to think critically about research and how to develop and test hypotheses, but also invaluable skills in writing and critically reviewing manuscripts and preparing and submitting innovative grant proposals. She has also further instilled in me the desire to persist, even if manuscripts or grants get rejected. I will leave my time as her graduate student well-prepared to continue my progression into an independent researcher.

I would also like to thank Dr. Douglas Jones, who is on my committee and has also served as an additional mentor within our laboratory. Dr. Jones has an unwavering enthusiasm for science that is contagious. From Dr. Jones I have learned the ability to develop hypotheses for any scientific question and how I might design experiments to test the hypothesis. This has been invaluable in my development critically reviewing the research of others and developing my own.

I would like to acknowledge the additional members of my committee, Dr. Marit Nilsen-Hamilton, Dr. Annette O'Connor, and Dr. Justin Greenlee, all of whom have dedicated time and effort in my development. I am grateful for the multi-disciplinary expertise and unique perspectives from my committee. All of the members have contributed to my development significantly in areas of biochemistry and cell-signaling, epidemiology, and pathology. I am grateful for their contribution.

Members of the Jones-Petersen laboratory group, both current and previous, including Paola Boggiatto, Katherine Gibson-Corely, Alex Osanya, Pedro Martinez, Marie Bockenstedt, Matt Brewer, Raeann Shimak, Rachel Juelsgaard, Sarah Mull, Ryan Schafbuch, and Valerie Culpepper deserve thanks for their support, friendship, and assistance with numerous projects. I would like to give special thanks to Alex, Katherine, and Paola, who trained me in proper laboratory techniques, and assisted in multiple projects, and Pedro Martinez, who helped with a good eye for image analysis and presentation, and provided good music for experimentation. Without everyone in the laboratory the research presented here would not have been possible.

I am grateful to all of the faculty and staff at Iowa State University who contributed to my graduate education. I have had the pleasure of learning from multiple members of the Immunobiology Graduate Program and the Department of Veterinary Pathology. I would like to acknowledge the excellent core facilities and support staff of the Immunobiology Interdepartmental Program, the Histopathology Laboratory, the Flow Cytometry Facility, the Office of Biotechnology, and Laboratory Animal Resources for their exceptional expertise and professionalism. I would also like to thank my cohort of pathology residents and

immunobiology graduate students. I have enjoyed sharing all of our in class and out of class interactions.

I would like to give a special thank you to our collaborators with whom I have performed a large amount of research. I would like to thank Drs. Selma Jeronimo and Mary Wilson for their additional mentorship. I learned what really matters in preventing neglected disease from extended conversations with Dr. Jeronimo in Brazil. I would like to thank Dr. Mary Wilson whose laboratory has always been a welcome place, and whose laboratory members are outstanding. I would also like to thank the Infectious Disease Research Institute in Seattle, Washington for partially funding my research and for peer review and grant support, including Drs. Malcolm Duthie and Randy Howard. I would also like to thank Dr. Charles Thoen, who helped me continue my interest in research while in private practice, and whose thoughtful advice helped me decide to return to complete my Ph.D.

I would like to thank all of the faculty of the Veterinary Pathology Department. Your support and education in anatomic pathology have been invaluable. The large number of seminars and course offerings in addition to individualized instruction through biopsy and necropsy service is truly valuable and appreciated by all of the residents.

I am thankful to funding sources which have made the pursuit of my graduate studies possible. I would like to thank the Morris Animal Foundation and Zoetis (formerly Pfizer) Animal Health for my fellowship to pursue graduate studies. I would like to thank NEWAID foundation for a fellowship to study VL in Brazil, and all of the experiences of working with neglected diseases in the real world. I would like to thank the National Institutes of Health for funding a significant portion of our research.

I would like to give a sincere thank you to individuals who have assisted my professional and personal development outside of Iowa State University. Dr. Merlin Kuennen and Jane have been my close friends and business partners for almost 13 years. I learned what hard work is and how to run a successful business from Merle, and I will forever be appreciative. When I left our practice to pursue my Ph.D. they gave and continue to give their full support, even considering the business burden of a young partner leaving. I would like to thank the late Dr. Brad Keuhl, whose loss was a huge tragedy in my life. From Brad I learned how to be a dad, to work all day (and sometimes all night), and set it down to go coach your children's baseball and basketball on the nights and weekends.

Finally I would like to thank my family. My father, Jan has always given me support and guidance. My late mother Vernell, who must have thought she went through high school five times, quizzing all of my siblings and I, helping us with homework and reports. She was truly the anchor of our family, and always just expected us to achieve. I would like to thank all of my sisters who set the academic bar high. I would also like to give a special thank you to Dr. John Hallberg and his wife Lois, for their guidance and support during stressful periods of the Ph.D. process, and their contribution to our children's lives as an extra set of grandparents. I would like to thank my mother-in-law Shirley, who has always been there for Staci and the girls, I appreciate everything you have done for our family.

I would like to thank my wife, Staci, whose support has been nothing short of amazing. From sitting at our desk late at night budgeting to figure a way to allow me to leave a stable career to pursue my Ph.D. to being supportive of my travel to Brazil, she has always given everything to our family. I will never be able to repay you for all of your sacrifices and support, but I am forever grateful. I would also like to thank my children,

Gabriella, Eva, and Vivienne, whose sacrifices come in the way of being patient with dad, and understanding, even if you can't figure out why I am still in college. Thank you, truly, to everyone who has contributed to my professional and personal life.

APPENDIX

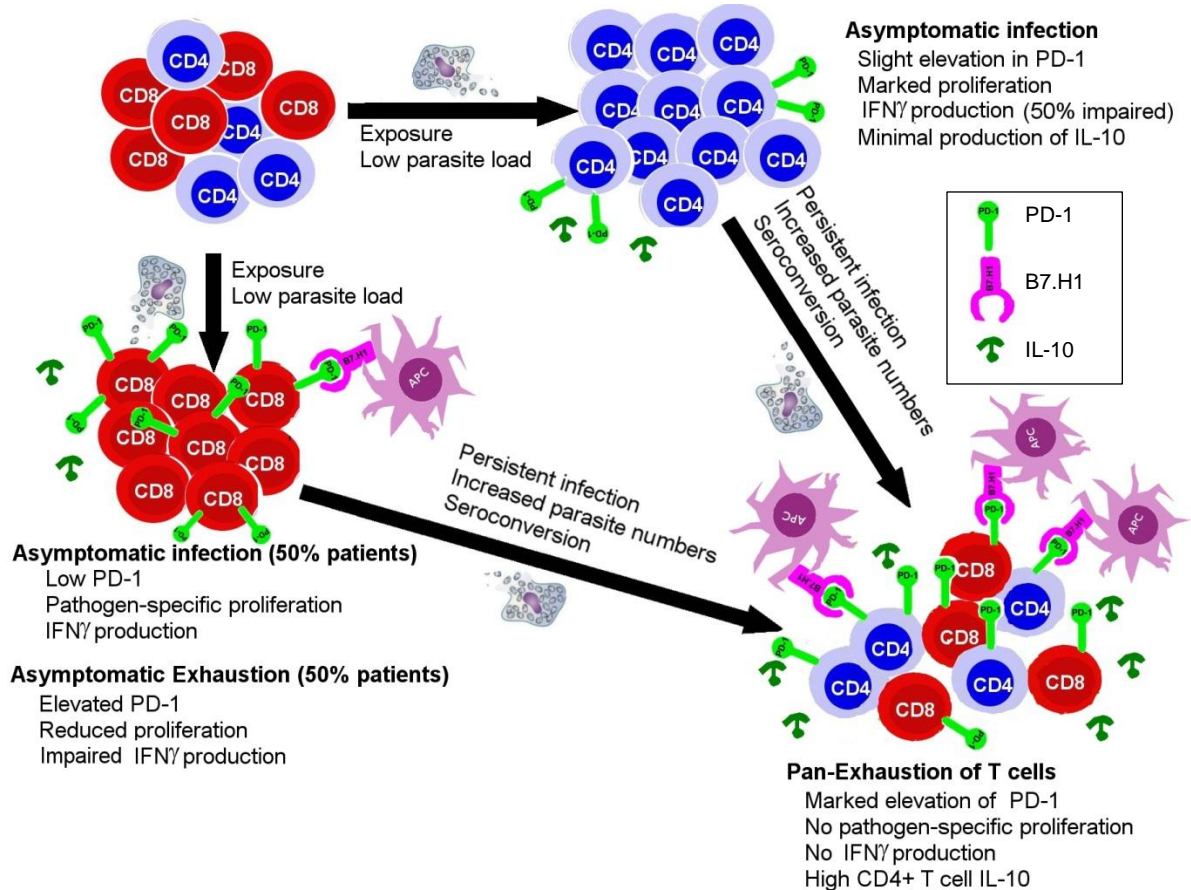


Figure A1. Model of pan-T cell exhaustion during visceral leishmaniasis – Naïve T cell population encounter *Leishmania infantum* at the time of infection. Exposure to a low parasite number and clearance results in memory T cell population capable of responding to subsequent infection or antigen via production of IFN γ , proliferation, with low expression of PD-1. With asymptomatic infection, CD8+ T cell populations from approximately 50% of these subclinically infected patients demonstrate characteristics of exhaustion, with impaired proliferation, impaired IFN γ production, and elevated surface expression of PD-1. With asymptomatic infection, CD4+ T cell populations are largely responsive, with approximately 50% of patients having impaired IFN γ only, with low PD-1 positivity. With persistent infection, including elevated parasite burden and seroconversion, pan-exhaustion ensues, with high IL-10, elevated PD-1 surface expression on both CD4+ and CD8+ T cells, and impaired T cell proliferation and IFN γ production in response to f-t *L. infantum*. With blockade of IL-10 or PD-1/B7.H1, a partial recovery of T cell functions is possible.